

LESSON 8

Lung Anatomy



The lungs are respiratory organs -- we use them to breathe. We breathe in order to get oxygen (O_2) and to get rid of carbon dioxide (CO_2).

We breathe in through the nose or mouth. The air then goes through the larynx and the trachea (also called the windpipe) and into the lungs. We breathe by using the diaphragm, a muscular membrane under the lungs. When the diaphragm contracts and pulls downwards, the lungs expand and air enters the lungs (inhalation). When the diaphragm relaxes, air is exhaled from the lungs.

When the air is in the lungs, it comes enters capillary-lined alveoli (singular alveolus). In the hollow alveoli, gas exchange occurs [oxygen (O_2) is absorbed by blood in the capillaries and carbon dioxide (CO_2) is gotten rid of].

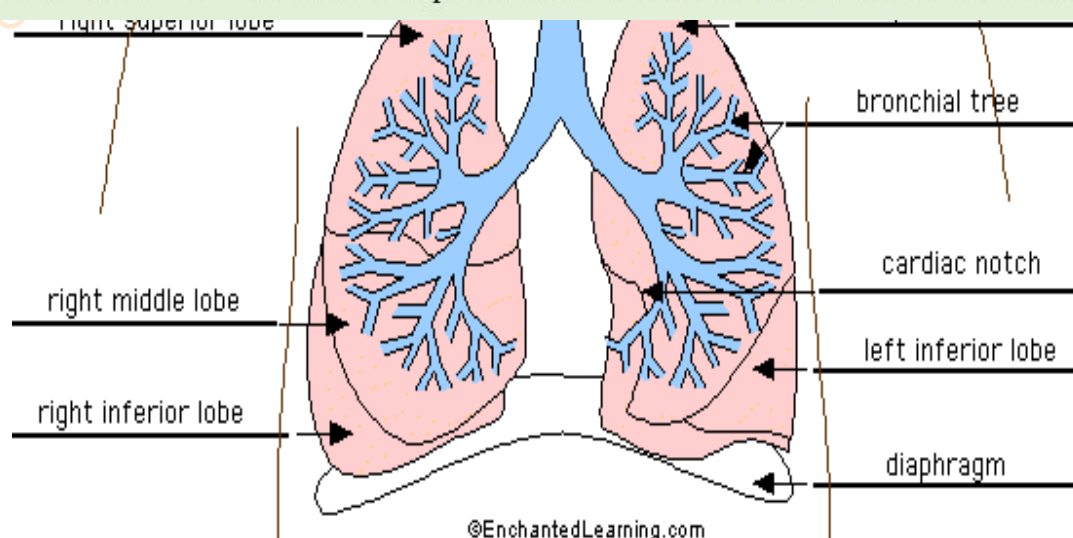
Copyright © 2018 Surely work.co

完全版テキストはレッスン前に担当講師から受け取って下さい

講師のスカイプチャットにテキスト名を送って下さい

Your teacher can send you the complete material.

Please ask them to send the complete version of this material before the lesson.



Lung Glossary

alveoli (singular alveolus) - hollow, capillary-lined structures within the lungs that are the site of gas exchange with the blood [the absorption of oxygen (O_2) and the loss of carbon dioxide (CO_2)]. Each human lung contains about 300 million alveoli.

bronchial tree - the system of airways within the lungs, which bring air from the trachea to the lung's tiny air sacs (alveoli).

cardiac notch - the indentation in the left lung that provides room for the heart.

diaphragm - a muscular membrane under the lungs. When it contracts and pulls downwards, the lungs expand and air enters the lungs (inhalation). When the diaphragm relaxes, air is exhaled from the lungs.

larynx - a muscular structure at the top of the trachea, containing the vocal cords.

left inferior lobe - the bottom lobe of the lung on the left side of the body.

left superior lobe - the top lobe of the lung on the left side of the body.

right inferior lobe - the bottom lobe of the lung on the right side of the body.

right middle lobe - the middle lobe of the lung on the right side of the body.

right superior lobe - the top lobe of the lung on the right side of the body.

trachea (windpipe) - the tube through which air travels from the larynx to the

Copyright © 2018 Surely work.co

完全版テキストはレッスン前に担当講師から受け取って下さい

講師のスカイプチャットにテキスト名を送って下さい

Your teacher can send you the complete material.

Please ask them to send the complete version of this material before the lesson.

Conditions affecting the Respiratory System

	<u>Definition</u>	<u>Cause</u>	<u>Effect (Symptoms)</u>
Asthma	Bronchial Asthma is the condition of subjects with widespread narrowing of the bronchial airways, which changes in severity over short	May be precipitated by exposure to one or more of a wide range of stimuli, including allergens, drugs (such as aspirin and other NSAIDs and beta blockers), exertion, emotion, infections, and air pollution. The onset of asthma is usually early in life and in atopic subjects	<u>Treatment:</u> is with bronchodilators, with or without corticosteroids, usually administered via aerosol or dry-powder inhalers, or – if the condition is more severe – via a nebulizer. Oral corticosteroids are reserved for patients who fail to respond adequately to these measures. Severe

Copyright © 2018 Surely work.co

完全版テキストはレッスン前に担当講師から受け取って下さい

講師のスカイプチャットにテキスト名を送って下さい

Your teacher can send you the complete material.

Please ask them to send the complete version of this material before the lesson.

wheezing, and difficulty in breathing.

into adulthood or even middle or old age.

help to reduce the frequency of attacks, as will the discouragement of smoking.

Cardiac Asthma occurs in left ventricular heart failure and must be distinguished from bronchial asthma, as the

treatment is quite different.

Bronchitis

Acute Bronchitis : Is caused by viruses or bacteria.

- Coughing
- The production of mucopurulent sputum.
- Narrowing of the bronchi due to spasmodic contraction.

Chronic Bronchitis : Is not

The disease is particularly prevalent in Britain in association with

- The patient coughs up excessive mucus secreted by enlarged bronchial

Copyright © 2018 Surely work.co

完全版テキストはレッスン前に担当講師から受け取って下さい

講師のスカイプチャットにテキスト名を送って下さい

Your teacher can send you the complete material.

Please ask them to send the complete version of this material before the lesson.

infections.

Emphysema

Pulmonary emphysema: The air sacs (alveoli) of the lungs are enlarged and damaged, which reduces the surface

Normal lung tissue contains:



Aveolar Sacs: normally expand and contract, but over-expand

Over-expansion of aveolar sacs leads to:

- Loss of elasticity
- Loss of surface area
- Loss of lung capacity
- Insufficient take-up of oxygen

Severe emphysema causes breathlessness/severe breathing difficulty, which is made worse by infections.

area for the exchange of oxygen and carbon dioxide.

It is particularly common in men in Britain and is associated with chronic bronchitis, smoking, and advancing age.

Surgical emphysema:

Air may escape into the tissues of the chest and neck from leaks in the lungs and oesophagus; occasionally air escapes into other tissues during surgery and

The presence of gas or air gives the affected tissues a characteristic crackling feeling to the touch.

Copyright © 2018 Surely work.co

完全版テキストはレッスン前に担当講師から受け取って下さい

講師のスカイプチャットにテキスト名を送って下さい

Your teacher can send you the complete material.

Please ask them to send the complete version of this material before the lesson.

Hay
Fever

A form of allergy due to the pollen of grasses, trees, and other plants, characterized by inflammation of the

X-rays. It is easily absorbed once the leak or production is stopped.

Pollens of grasses, trees, and other plants.

The symptoms of sneezing, running or blocked nose, and watering eyes are due to histamine release and often respond to treatment with antihistamines. If the allergen is identified it may be possible to undertake desensitization

lining of
the nose
and
sometimes
of the
conjunctiva
.

**Pleuri
sy**

Inflammati
on of the
pleura.

Often due to
pneumonia in the
underlying lung.
The normally shiny
and slippery pleural
surfaces lose their
sheen and become
slightly sticky, so
that there is pain
on deep breathing

- Pain on deep breathing.
- A characteristic 'rub' can be heard through a stethoscope.

Copyright © 2018 Surely work.co

完全版テキストはレッスン前に担当講師から受け取って下さい

講師のスカイプチャットにテキスト名を送って下さい

Your teacher can send you the complete material.

Please ask them to send the complete version of this material before the lesson.

caused by
bacteria, in
which the
air sacs
(alveoli)
become
filled with
inflammato
ry cells and
the lung
becomes
solid.

Pneumonias may
be classified in
different ways:

- According to X-ray appearance,
- According to the infecting organism,
- According to the clinical environmental circumstances under which the infection is acquired (e.g. 'community-

- Fever, Malaise, Headaches etc., together with
- Cough and chest pain.

Treatment:
Appropriate antibiotic therapy, based on the clinical situation and on microbiological studies, results in complete recovery in the majority of patients.

		acquired pneumonia', 'hospital-acquired (nosocomial) pneumonia').	
Rhinitis	Inflammation of the mucous membrane of the nose.	It may be caused by: <ul style="list-style-type: none"> • Virus infection (acute rhinitis), • An allergic reaction (allergic rhinitis). 	In atrophic rhinitis the mucous membrane becomes thinned and fragile. In perennial (or vaso motor) rhinitis there is overgrowth of, and increased secretion by, the membrane.
Tuber	An	<u>Bacillus inhaled</u>	Symptoms of the

Copyright © 2018 Surely work.co

完全版テキストはレッスン前に担当講師から受け取って下さい

講師のスカイプチャットにテキスト名を送って下さい

Your teacher can send you the complete material.

Please ask them to send the complete version of this material before the lesson.

characterized by the formation of nodular lesions (tubercles) in the tissues.	up a primary tubercle and spreads to the nearest lymph nodes (the primary complex). Natural immune defences may heal it at this stage; alternatively the disease may smoulder for months or years and fluctuate with the patient's resistance. Many people become	throughout the body (military tuberculosis), or migrate to the meninges to cause tuberculous meningitis. <u>Treatment:</u> Tuberculosis is curable by various combinations of antibiotics. Preventative measures in the UK include the detection of cases by X-ray screening of vulnerable populations and inoculation with
-------------------------------------------------------------------------------	-------------------------------------------------------------------------------------------------------------------------------------------------------------------------------------------------------------------------------------------------------------------	------------------------------------------------------------------------------------------------------------------------------------------------------------------------------------------------------------------------------------------------------------------------------------------------------------------------------------

infected but show no symptoms.

Others develop a chronic infection and can transmit the bacillus by coughing and sneezing.

Bacillus entering by mouth (usually in infected cow's milk):

Set up a primary complex in the abdominal lymph nodes, leading to peritonitis, and

BCG vaccine of those with no immunity to the disease.

Copyright © 2018 Surely work.co

完全版テキストはレッスン前に担当講師から受け取って下さい

講師のスカイプチャットにテキスト名を送って下さい

Your teacher can send you the complete material.

Please ask them to send the complete version of this material before the lesson.

