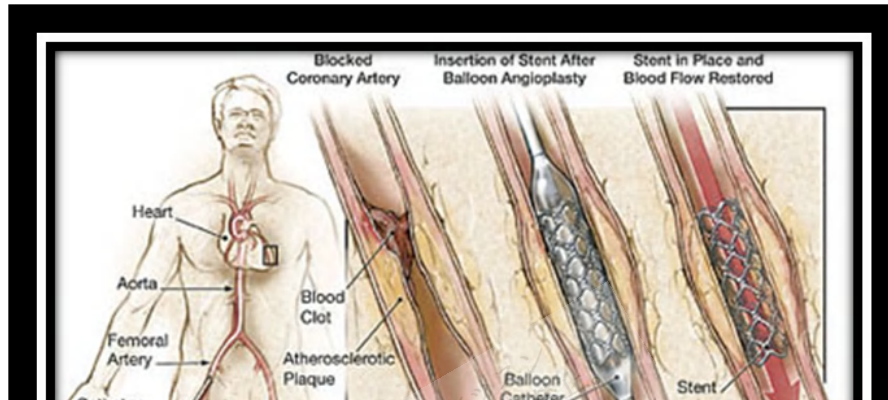


# Percutaneous Coronary Interventions (PCI)



Copyright © 2018 Surely work.co

完全版テキストはレッスン前に担当講師から受け取って下さい

講師のスカイプチャットにテキスト名を送って下さい

Your teacher can send you the complete material.

Please ask them to send the complete version of this material before the lesson.

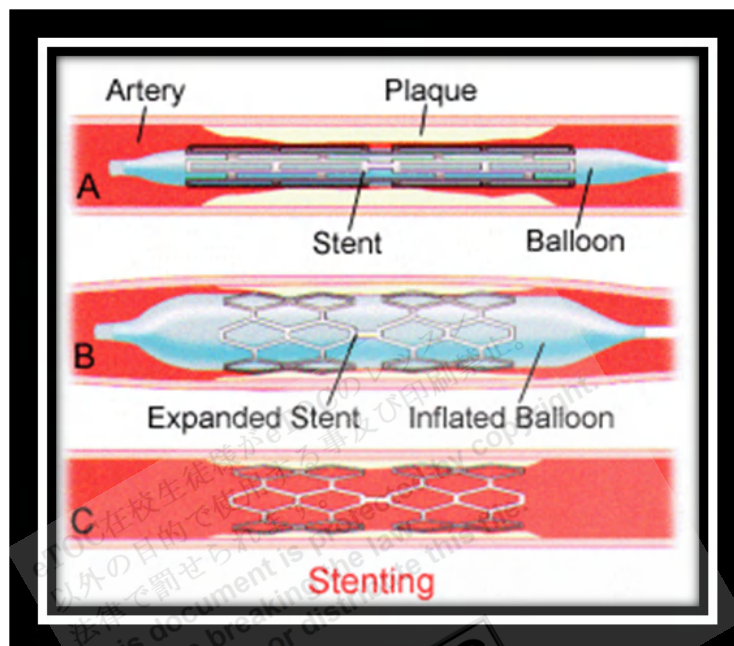
transmural ST-segment-elevation MI. Elective PCI may be appropriate for post-MI patients who have recurrent or inducible angina before hospital discharge and for patients who have angina and remain symptomatic despite medical treatment. Percutaneous transluminal angioplasty (PTA) is used to treat peripheral arterial disease.

**Procedure:** PTCA is done via percutaneous femoral, radial, or brachial artery puncture. A guiding catheter is inserted into a large peripheral artery and threaded to the appropriate **coronary ostium**. A balloon-tipped catheter, guided by **fluoroscopy** or **intravascular ultrasonography**, is aligned within the stenosis, then inflated to disrupt the **atherosclerotic plaque** and **dilate** the artery. Angiography is repeated after the procedure to document any changes. The procedure is commonly done in 2 or 3 vessels as needed.

**Stents:** Stents are most useful for

- Short lesions in large native coronary arteries not previously treated with PTCA
- Focal lesions in **saphenous vein grafts**
- Treatment of abrupt closure during PTCA

Stents are now used frequently for acute MI, ostial or left main disease, chronic total occlusions, and bifurcation lesions..



<http://asrmedassist.com/gqhc/galleryimg/c728hr80stent1.gif>

**Types of stents:** Bare metal stents (BMS) are made of **nickel-titanium alloy**. **Drug eluting stents** (DES) have drugs (eg, 1st-generation: **sirolimus, paclitaxel**; 2nd-generation: **everolimus, zotarolimus**) bonded to the metal that limit **neointimal** proliferation to reduce the risk of **restenosis**. In **intracoronary brachytherapy**, the site of stenosis is exposed to radiation in the form of small pellets embedded in a nylon ribbon temporarily (eg, 30 min) placed in the coronary artery prior to stenting. This technique appears to decrease the risk of early restenosis, but it is unclear whether later stenosis is slightly increased; trials are ongoing. Radioactive stents have not proven effective at limiting restenosis. **Biodegradable** stents are currently in clinical trials.

**Anticoagulation:** Various anticoagulation regimens are used during and after angioplasty to reduce the incidence of thrombosis at the site of balloon dilation.

**Thienopyridines** (**clopidogrel, prasugrel, ticagrelor**) and **glycoprotein IIb/IIIa** inhibitors are the standard of care for patients with unstable non-ST-segment elevation MI. Thienopyridines (often in combination with aspirin) are continued for 9 to 12 mo after PCI. Ca channel blockers and nitrates may also reduce risk of coronary spasm.

## Contraindications

**Absolute contraindications** include

- Lack of cardiac surgical support
- Critical left main coronary stenosis without collateral flow from a native vessel or previous bypass graft to the left anterior descending artery

**Relative contraindications** include

- **Coagulopathy**
- **Hypercoagulable states**
- Diffusely diseased vessels without focal stenoses
- A single diseased vessel providing all perfusion to the myocardium
- Total occlusion of a coronary artery
- Stenosis < 50%

## Complications

The main complications of balloon angioplasty and stent placement are

- Thrombosis
- Restenosis
- Arterial dissection

Thrombosis causes complete blockage and may occur at any time—acutely (immediately during or after the procedure), subacutely (within 30 days), or late (> 30 days). Stent thrombosis may be due to inadequate stent expansion or **apposition** at the time of the procedure, discontinuation of dual antiplatelet therapy (eg, from nonadherence, need for noncardiac surgery), or both.

Restenosis is typically due to collagen deposition and thus does not occur until several weeks after the procedure or later; it may cause partial or, less commonly, complete vessel blockage. Dissection is usually detected immediately. Insertion of another stent often reopens the dissected segment.

With balloon angioplasty, risk of acute thrombosis is about 5 to 10%, risk of subacute restenosis is about 5%, and the overall restenosis rate is about 30 to 45%. Use of stents has almost eliminated the need for emergency coronary artery bypass grafting following PCI. With stent use, the rate of acute and subacute thrombosis or restenosis is < 1%. With BMS, risk of late restenosis is decreased to 20 to 30%. Use of a DES lowers late restenosis risk to about 5 to 10%. However, using a DES increases risk of late stent thrombosis, about 0.6%/yr up to 3 yr.

Complications besides restenosis are similar to those of coronary angiography, although risk of death, MI, and stroke is greater. Of all angiographic procedures, PCI has the highest risk of contrast nephropathy; this risk can be reduced by **preprocedural hydration** and possibly by use of a nonionic contrast agent or hemofiltration in patients with preexisting renal insufficiency. Stent placement, in addition to the above, has complications of bleeding secondary to aggressive adjunctive anticoagulation, side **branch occlusion**, and **stent embolism**.

Reference: <http://www.merckmanuals.com>

eTOC在校生徒様がeTOCのレッスン  
以外の目的で使用すること及び印刷禁止。  
法律で罰せられます。  
This document is protected by copyright.  
You are breaking the law  
if you copy or distribute this file.

**eTOC**  
English Teachers On Call