

## Radionuclide Imaging

**Radionuclide imaging** uses a special detector (gamma camera) to create an image following injection of radioactive material. This test is done to evaluate coronary artery disease (CAD), valvular or congenital cardiac disorders, cardiomyopathy, and other cardiac disorders. Radionuclide imaging exposes patients to less radiation than do comparable x-ray studies. However, because the radioactive material is retained in the patient briefly, sophisticated radiation alarms (eg, in airports) may be triggered by the patient for several days after such testing.

SPECT in Recent-Onset Angina



Copyright © 2018 Surely work.co

完全版テキストはレッスン前に担当講師から受け取って下さい

講師のスカイプチャットにテキスト名を送って下さい

Your teacher can send you the complete material.

Please ask them to send the complete version of this material before the lesson.

which uses a rotating camera system and **tomographic** reconstruction to produce a 3-dimensional image, is more common in the US. With multihead SPECT systems, imaging can often be completed in  $\leq 10$  min. Visual comparison of stress and delayed images can be supplemented by quantitative displays. With SPECT, inferior and posterior abnormalities and small areas of infarction and the vessels responsible for infarction can be identified. The mass of infarcted and viable myocardium can be quantified, helping determine prognosis.

### **Myocardial Perfusion Imaging**

In **myocardial perfusion imaging**, IV radionuclides are taken up by cardiac tissues in rough proportion to perfusion; thus, areas of decreased uptake represent areas of relative or absolute ischemia. For this reason, myocardial perfusion imaging is used with stress testing to evaluate patients with chest pain of uncertain origin, to determine the functional significance of coronary artery stenosis or collateral vessels seen on

angiography, and to evaluate the success of **reperfusion interventions** (eg, coronary artery bypass grafting [CABG], percutaneous intervention, **thrombolysis**). After acute MI, myocardial perfusion imaging can help estimate prognosis because it can show extent of the perfusion abnormality due to acute MI, extent of scarring due to previous infarcts, and residual peri-infarct or other areas of **reversible ischemia**.

Radioactive thallium-201 ( $^{201}\text{Tl}$ ), which acts as a K analog, was the original tracer used in stress testing. It is injected at peak stress and imaged with SPECT, followed 4 h later by injection of 1/2 the original dose during rest and by repeat SPECT. The goal of this protocol is to evaluate reversible perfusion defects that may warrant intervention. After stress testing, the perfusion imbalance between normal coronary arteries and those **distal** to a stenosis appears as a relative decrease in  $^{201}\text{Tl}$  uptake in the areas perfused by the stenosed arteries. Sensitivity of stress testing with  $^{201}\text{Tl}$  for CAD is similar whether imaging is done after exercise or pharmacologic stress.

Copyright © 2018 Surely work.co

完全版テキストはレッスン前に担当講師から受け取って下さい

講師のスカイプチャットにテキスト名を送って下さい

Your teacher can send you the complete material.

Please ask them to send the complete version of this material before the lesson.

transit function studies (with ventriculography) may be used with perfusion imaging.

Other radionuclides include iodine-123 ( $^{123}\text{I}$ )–labeled fatty acids, which produces cold spots where myocardium is ischemic; gallium citrate-67 ( $^{67}\text{Ga}$ ), which accumulates in sites of active inflammation (eg, in acute inflammatory cardiomyopathy); and  $^{123}\text{I}$  metaiodobenzylguanidine, a neurotransmitter analog taken up and stored in neurons of the sympathetic nervous system and used in research to evaluate heart failure, diabetes, certain arrhythmias, and arrhythmogenic right ventricular dysplasia.

**Attenuation** of myocardial activity by overlying soft tissue may cause false-positive results. Attenuation by breast tissue in women is especially common. Attenuation by the diaphragm and abdominal contents may produce **spurious** inferior wall defects in both sexes but is more common among men. Attenuation is more likely with  $^{99\text{m}}\text{Tc}$  than with  $^{201}\text{Tl}$ .

Table 6

**Technetium-99m Myocardial Perfusion Markers**

Marker	Characteristics
<sup>99m</sup> Tc sestamibi	<p>Myocardial uptake is slower than that with thallium, but there is little myocardial washout, allowing timing flexibility; patients with acute symptoms can be injected with sestamibi immediately and imaged several hours later.</p> <p>Uptake depends more on blood flow than on viable myocardium; viable regions with low blood flow may be misclassified as scar.</p> <p>Studies may be done on a single or on separate days,</p>

Copyright © 2018 Surely work.co

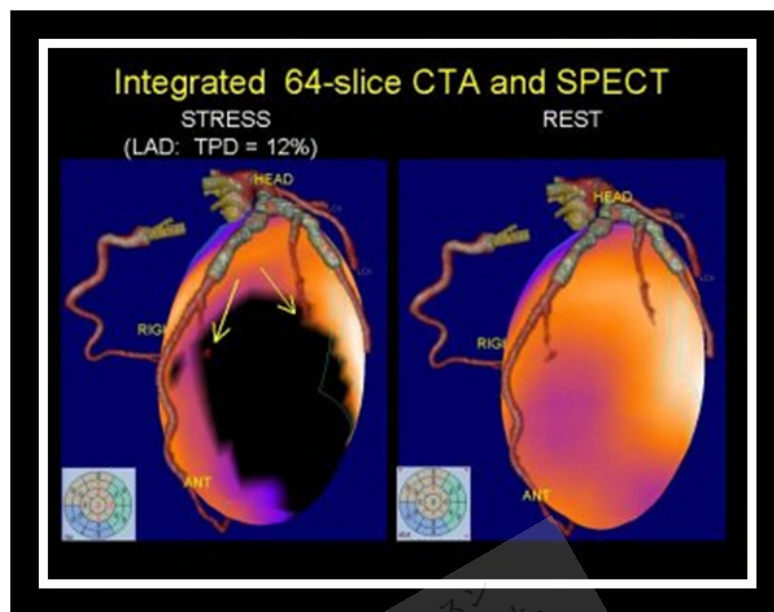
完全版テキストはレッスン前に担当講師から受け取って下さい

講師のスカイプチャットにテキスト名を送って下さい

Your teacher can send you the complete material.

Please ask them to send the complete version of this material before the lesson.

teboroxime	<p>rapid washout; half of peak myocardial activity is gone by 10 min.</p> <p>Because of its rapid dynamics, use with treadmill exercise is difficult.</p> <p>Preliminary studies suggest that stress-redistribution testing may be completed within 15 min of pharmacologic stress. Coronary artery disease may be detectable by analyzing myocardial washout of the tracer after injection at rest, without the need for stress.</p>
------------	---



<http://www.theheart.org/displayItem.do?primaryKey=795303&type=img>

Copyright © 2018 Surely work.co

完全版テキストはレッスン前に担当講師から受け取って下さい

講師のスカイプチャットにテキスト名を送って下さい

Your teacher can send you the complete material.

Please ask them to send the complete version of this material before the lesson.

### Radionuclide Ventriculography

**Radionuclide ventriculography** is used to evaluate ventricular function. It is useful for measuring resting and exercise ejection fraction in CAD, valvular heart disease, and congenital heart disease. Some clinicians prefer it for serial assessment of ventricular function in patients taking cardiotoxic cancer chemotherapy (eg, anthracyclines). However, radionuclide ventriculography has been largely replaced by echocardiography, which is less expensive, does not require radiation exposure, and theoretically can measure ejection fractions as accurately.

$^{99m}\text{Tc}$ -labeled RBCs are injected into the ventricles. Left ventricular (LV) and right ventricular (RV) function can be evaluated by first-transit studies (a type of beat-to-beat evaluation) or by gated (ECG-synchronized) blood pool imaging done over several minutes (**multiple-gated acquisition** [MUGA]). Either study can be done during rest or

after exercise. **First-transit studies** are rapid and relatively easy, but MUGA provides better images and is more widely used.

In first-transit studies, 8 to 10 cardiac cycles are imaged as the marker mixes with blood and passes through the central circulation. First-transit studies are ideal for assessing RV function and intracardiac shunts.

In MUGA, imaging is synchronized with the R wave of the ECG. Multiple images are taken of short, sequential portions of each cardiac cycle for 5 to 10 min. Computer analysis generates an average blood pool configuration for each portion of the cardiac cycle and synthesizes the configurations into a continuous cinematic loop resembling a beating heart.

MUGA can **quantitate** numerous indexes of ventricular function, including regional wall motion. ejection fraction (EF): ratio of stroke volume to end-diastolic volume. ejection

Copyright © 2018 Surely work.co

完全版テキストはレッスン前に担当講師から受け取って下さい

講師のスカイプチャットにテキスト名を送って下さい

Your teacher can send you the complete material.

Please ask them to send the complete version of this material before the lesson.

**LV:** MUGA is useful for detecting **LV aneurysms**; sensitivity and specificity are > 90% for typical anterior or **anteroapical true aneurysms**. Conventional gated blood pool imaging shows **inferoposterior LV aneurysms** less well than it shows anterior and lateral aneurysms; additional views are required. Gated SPECT imaging takes longer (about 20 to 25 min with a multihead camera) than a single planar gated view (5 to 10 min) but shows all portions of the ventricles.

**RV:** MUGA is used to assess **RV function** in patients who have a lung disorder or an inferior LV infarct that may involve the RV. Normally, RVEF (40 to 55% with most techniques) is lower than LVEF. RVEF is subnormal in many patients with pulmonary hypertension and in patients with RV infarction or cardiomyopathy affecting the RV. Idiopathic cardiomyopathy is usually characterized by **biventricular dysfunction**, unlike typical CAD, which usually causes more LV than RV dysfunction.

**Valves:** MUGA can be used with rest-stress protocols to assess valvular disorders that result in LV volume overload. In **aortic regurgitation**, a reduction in resting EF or no increase in EF with exercise is a sign of **deteriorating cardiac function** and may indicate a need for valvular repair. MUGA also can be used to calculate the **regurgitant fraction** in regurgitation of any valve. Normally, the stroke volume of the 2 ventricles is equal. However, in patients with left-sided valvular regurgitation, LV stroke volume exceeds that of the RV by an amount proportional to the regurgitant fraction. Thus, if the RV is normal, the regurgitant fraction of the LV can be calculated from the LV:RV stroke volume ratio.

**Shunts:** With MUGA and commercially available computer programs, size of a congenital shunt can be quantified by the stroke volume ratio or, during the first transit of the marker, by the ratio of abnormal early pulmonary recirculation of radioactivity to total pulmonary radioactivity.

Copyright © 2018 Surely work.co

完全版テキストはレッスン前に担当講師から受け取って下さい

講師のスカイプチャットにテキスト名を送って下さい

Your teacher can send you the complete material.

Please ask them to send the complete version of this material before the lesson.