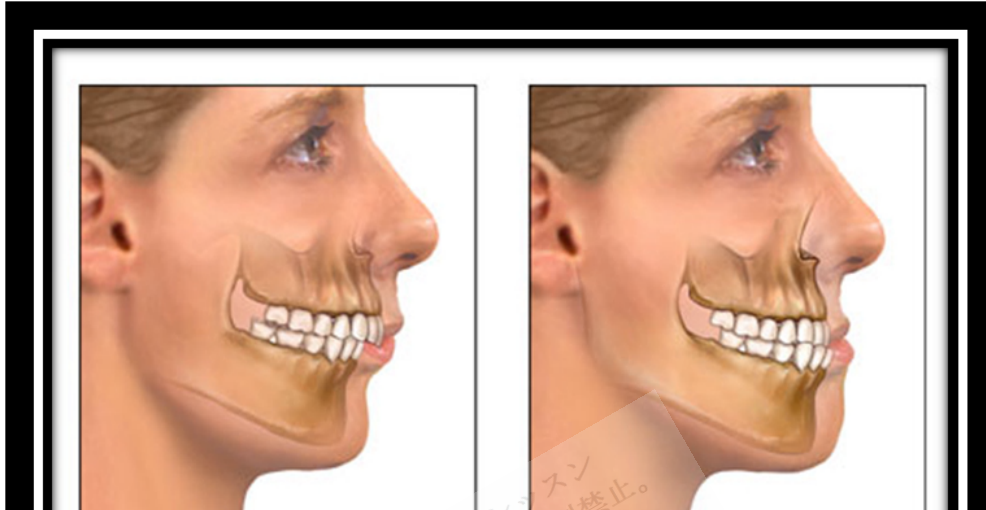


Malocclusion



Copyright © 2018 Surely work.co

完全版テキストはレッスン前に担当講師から受け取って下さい

講師のスカイプチャットにテキスト名を送って下さい

Your teacher can send you the complete material.

Please ask them to send the complete version of this material before the lesson.

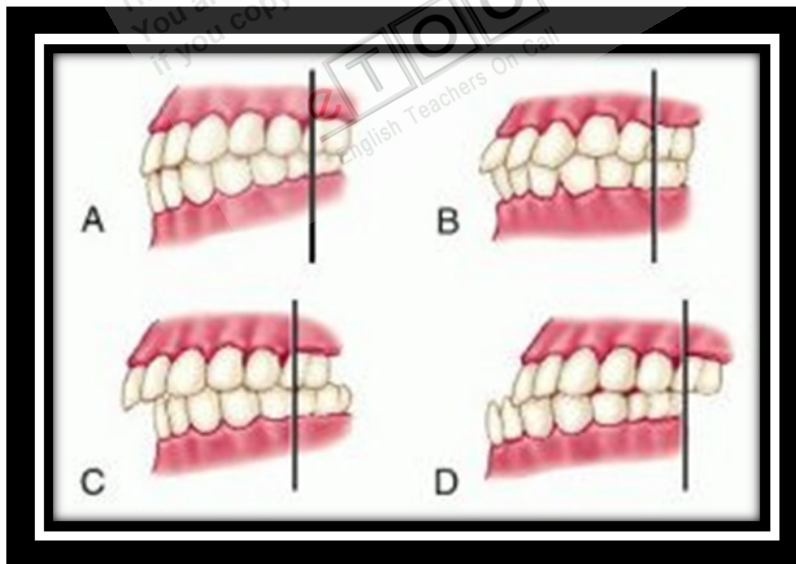
a smooth curve, with the maxillary anterior teeth overlying the upper third of the mandibular anterior teeth. The **buccal** (outer) cusps of the maxillary posterior teeth are external to the corresponding cusps of the mandibular posterior teeth. In most cases, the anterior **buccal cusp** of the maxillary 1st permanent molar fits into the anterior buccal groove of the mandibular 1st molar. Because the outer parts of all maxillary teeth are normally external to the mandibular teeth, the lips and cheeks are displaced from between the teeth so that they are not bitten. The **lingual** (inner) surfaces of the lower teeth form a smaller arc than those of the upper teeth, confining the tongue and minimizing the likelihood of its being bitten. All the maxillary teeth should contact the corresponding mandibular teeth, so that the masticatory forces (which may be > 150 lb in the molar region and 250 lb when clenching during sleep) are widely distributed. If these forces are applied to only a few teeth, those teeth may eventually become mobile.

Etiology

Causes of malocclusion include

- Size mismatch between jaw and teeth
- Certain oral habits (eg, thumb-sucking, tongue thrusting)
- Missing teeth
- Certain **congenital defects**

Malocclusion most often results from jaw and tooth size discrepancies (ie, the jaw is too small or the teeth are too large for the jaw to accommodate them in proper alignment). People who habitually suck their thumb or push their tongue up against their front teeth may cause gradual protrusion of the upper incisors. When permanent teeth are lost, adjacent teeth shift and opposing teeth may **extrude**, causing malocclusion unless a bridge, implant, or partial denture is worn to prevent these movements. When children lose deciduous teeth prematurely, the teeth move posterior in the arch or the permanent 1st molars often drift forward, leaving insufficient space for other permanent teeth to erupt. Malocclusion after facial trauma may indicate tooth displacement and/or **alveolar bone** or jaw fractures. In **ectodermal dysplasia** or **Down syndrome**, malocclusions may result from having too few teeth.



<http://img.tfd.com/dorand/thumbs/malocclusion.jpg>

Evaluation

Occlusion is checked on both sides of the mouth by retracting each cheek with a tongue depressor while telling the patient to close on the back teeth;

telling patients to bite may mistakenly cause them to close on their incisors (as in biting a piece of fruit), which gives the false appearance of malocclusion of the back teeth. Malocclusion sometimes is identified as early as the first dental visit (age 1 yr). Early identification may make later treatment easier and more effective.

Treatment

Malocclusions are corrected primarily for aesthetic and psychologic reasons. However, in some cases, treatment may increase resistance to caries (in specific teeth), to anterior tooth fracture, and, possibly, to periodontal disease or stripping of the gingiva on the palate. Treatment may improve speech and **mastication** as well. Occlusion can be improved by aligning teeth properly, by selectively grinding teeth and restorations that contact prematurely, and by inserting crowns or onlays to build up tooth surfaces that are below the plane of occlusion.

Orthodontic appliances (braces) apply a continuous mild force to teeth to gradually remodel the surrounding alveolar bone. Extraction of one or more permanent teeth (usually a 1st premolar) may be needed to allow other teeth to be repositioned or to erupt into a stable alignment. After the teeth are properly aligned, the patient wears a plastic-and-wire retainer 24 h/day initially, then only at night for 2 to 3 yr.

When orthodontic treatment alone is insufficient, surgical correction of jaw abnormalities contributing to malocclusion (**orthognathic surgery**) may be indicated.

Reference: <http://www.merckmanuals.com>