

# Oral Growths

**Growths** can originate in any type of tissue in and around the mouth, including connective tissues, bone, muscle, and nerve. Most commonly, growths form on the lips, the sides of the tongue, the floor of the mouth, and the soft palate. Some growths cause pain or irritation. Growths may be noticed by the patient or discovered only during routine examination.

## **Etiology**

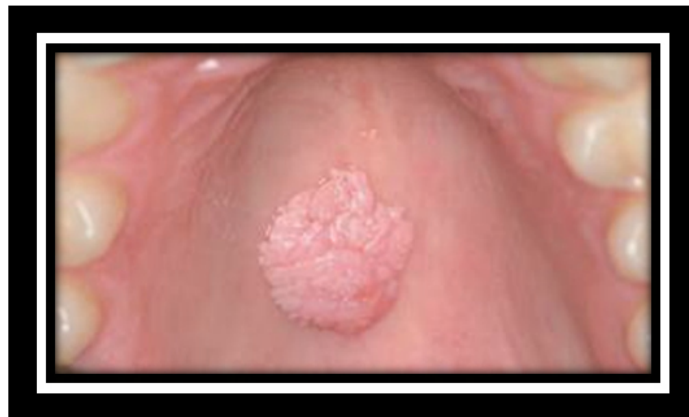Oral growths can be

- Benign
- Dysplastic
- Malignant

**Benign growths:** Most oral growths are benign; there are numerous types.

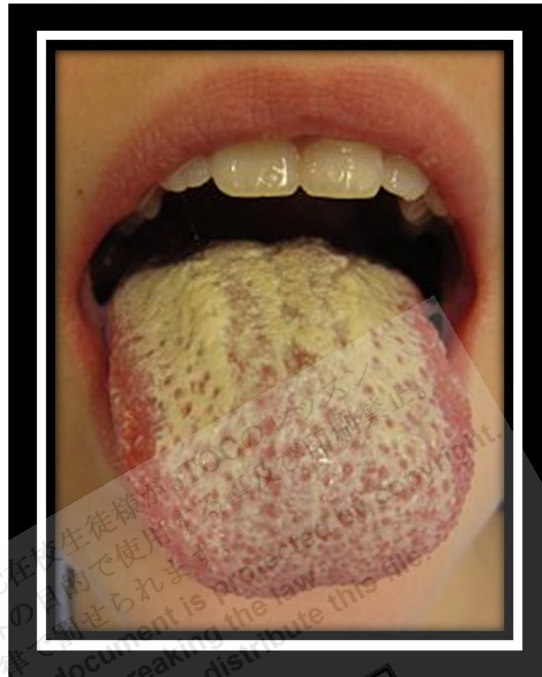
**Chronic irritation** can cause a persistent lump or raised area on the **gingiva**. Benign growths due to irritation are relatively common and, if necessary, can be removed by surgery. In 10 to 40% of people, benign growths on the gingiva reappear because the irritant remains. Occasionally such irritation, particularly if it persists over a long period of time, can lead to cancerous changes.

**Warts** may occur in the mouth. Ordinary warts (**verrucae vulgaris**) can infect the mouth if a person sucks or chews one that is growing on a finger. Genital warts, caused by human **papillomavirus** infection may also occur in the oral cavity when transmitted through oral sex.



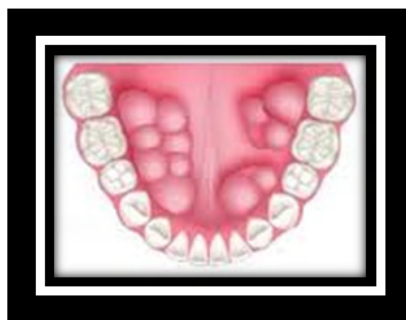<http://t1.gstatic.com/images?q=tbn:ANd9GcTT7kpQWix6qzfp9KEP0W3pQ6idkolCNiu8jHYehb2oEnvDpMZgAA>

**Oral candidiasis** often appears as white, cheesy plaques that stick tightly to the **mucus membranes** and leave red erosions when wiped off. Thrush is most common among patients with diabetes or **immunocompromise** and among those who are taking antibiotics.



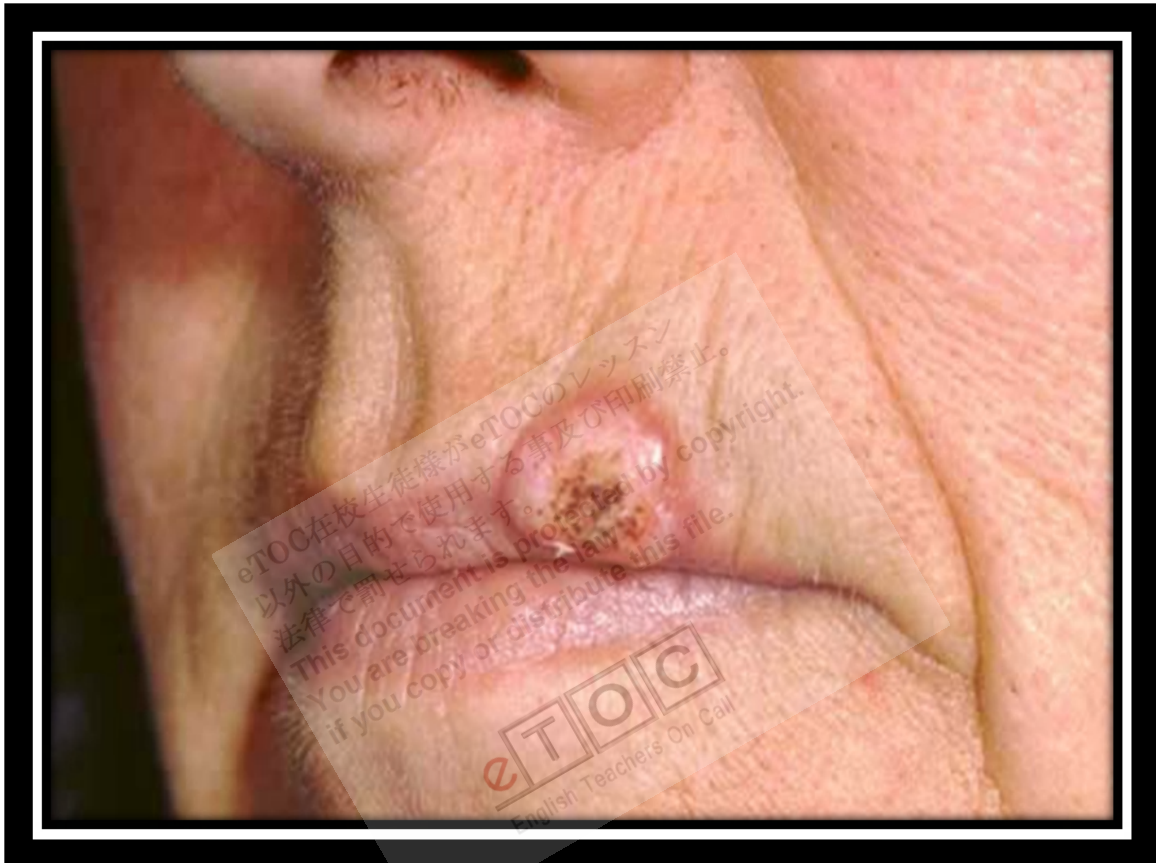<http://upload.wikimedia.org/wikipedia/commons/thumb/b/bf/Thrush.JPG/230px-Thrush.JPG>

A **torus palatinus** is a slow-growing, rounded projection of bone that forms in the midline of the hard palate or on the inner aspect of the **mandible**. This hard growth is both common and harmless. Even a large growth can be left alone unless it gets **traumatized** during eating or the person needs a denture that covers the area. Multiple bony growths in the mouth may indicate familial **adenomatous polyposis**, a hereditary disorder of the **GI tract** that involves multiple **colorectal polyps**.



<http://www.udent.com/info/images/tori.jpg>

**Keratoacanthomas** are benign growths that form on the lips and other sun-exposed areas, such as the face, forearms, and hands. A **keratoacanthoma** usually reaches its full size of about 1 to 3 cm or more in diameter within 1 or 2 mo, then begins to shrink after another few months and may eventually disappear without treatment.

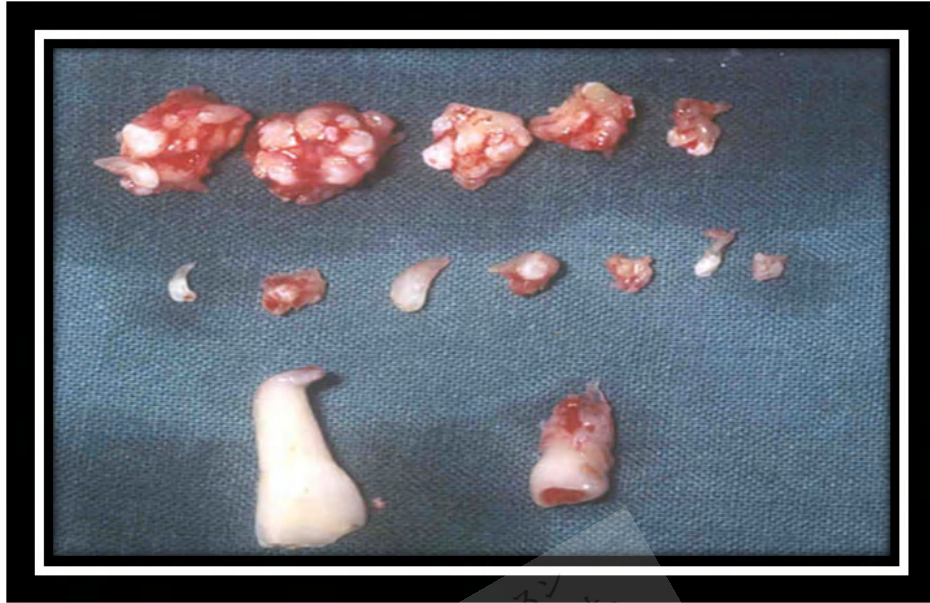

<http://medical.cdn.patient.co.uk/images/om2336a.jpg>

Many kinds of **cysts** cause jaw pain and swelling. Often they are associated with an impacted wisdom tooth and can destroy considerable areas of the mandible as they expand. Certain types of cysts are more likely to recur after surgical removal. Various types of cysts may also develop in the floor of the mouth. Often, these cysts are surgically removed because they make swallowing uncomfortable or because they are unattractive.

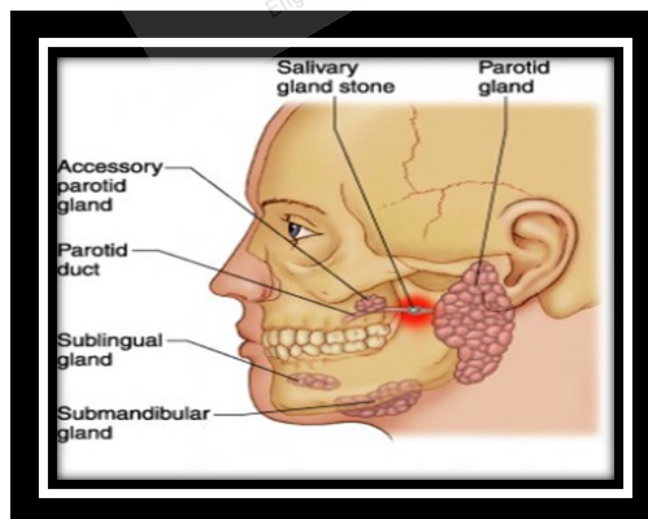
**Odontomas** are overgrowths of tooth-forming cells that look like small, misshapen extra teeth. In children, they may get in the way of normal tooth eruption. In adults, they may push teeth out of alignment. They are usually removed surgically.





[http://www.odontologia-online.com/casos/part/RAR/RAR02/odontomas\\_2.jpg](http://www.odontologia-online.com/casos/part/RAR/RAR02/odontomas_2.jpg)

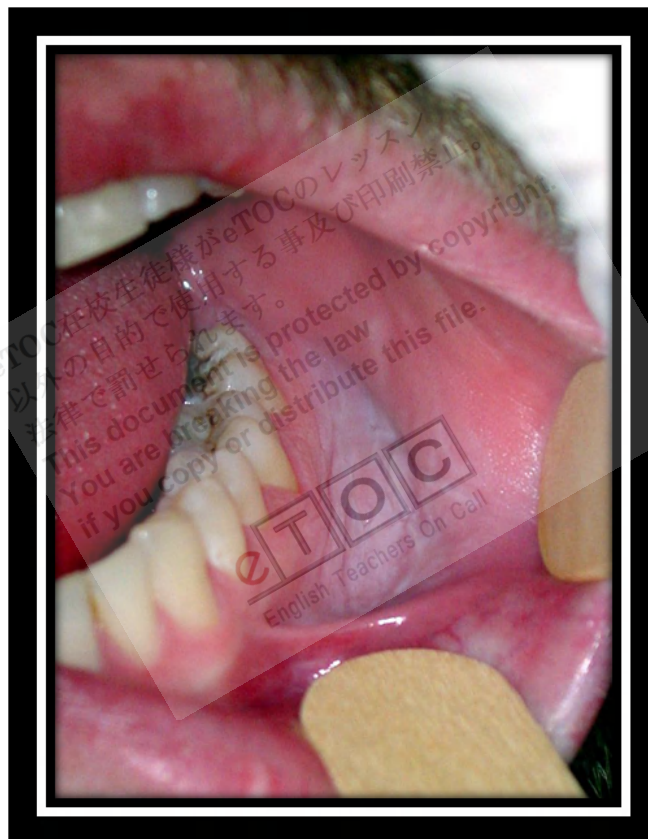**Salivary gland tumors** are mostly (75 to 80%) benign, slow-growing, and painless. They usually occur as a single, soft, movable lump beneath normal-appearing skin or under the **buccal mucosa**. Occasionally, when hollow and fluid-filled, they are firm. The most common type is a **pleomorphic adenoma (mixed tumor)** and it occurs mainly in women > age 40. Pleomorphic adenomas can become malignant and are removed surgically. Unless completely removed, this type of tumor is likely to recur. Other types of benign tumors are also removed surgically but are much less likely to become malignant or recur.



[http://www.intelligentdental.com/wp-content/uploads/2010/02/sal\\_g\\_st-300x299.jpg](http://www.intelligentdental.com/wp-content/uploads/2010/02/sal_g_st-300x299.jpg)

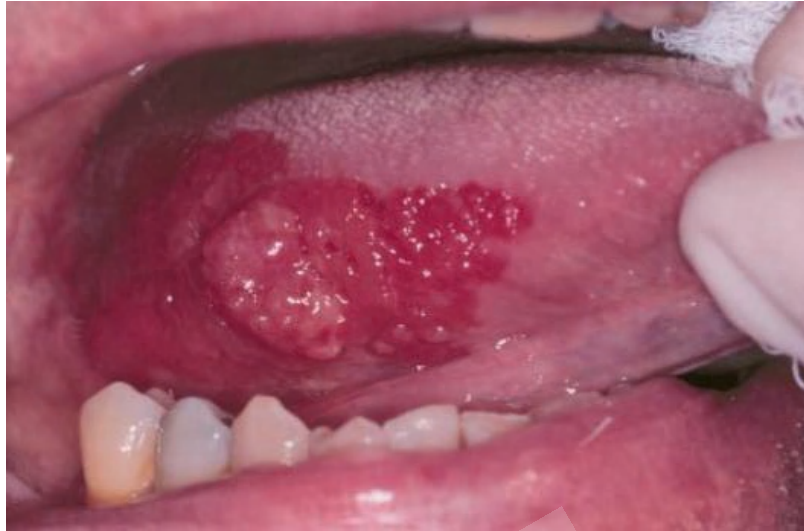**Dysplastic changes:** White, red, or mixed white-red areas that are not easily wiped away, persist for > 2 wk, and are not definable as some other condition may be dysplastic. The same risk factors are involved in dysplastic changes as in malignant growths, and dysplastic changes may become malignant if not removed.

**Leukoplakia** is a flat white spot that may develop when the oral mucosa is irritated for a long period. The irritated spot appears white because it has a thickened layer of **keratin**, which normally is less abundant in the oral mucosa.



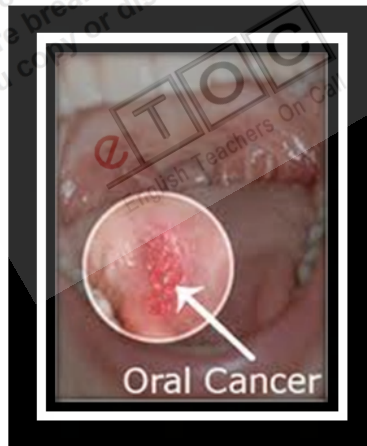
<http://www.tobacco-facts.info/images/20050310-oral-leukoplakia-750-1.jpg>

**Erythroplakia** is a red and flat or worn away area that results when the oral **mucosa thins**. The area appears red because the underlying capillaries are more visible. Erythroplakia is a much more ominous predictor of oral cancer than leukoplakia.



<http://www.exodontia.info/sitebuilder/images/Oral-Erythroplakia-527x348.jpg>

**Oral cancer:** People who use tobacco, alcohol, or both are at much greater risk (up to 15 times) of oral cancer. For those who use chewing tobacco and snuff, the insides of the cheeks and lips are common sites. In other patients, the most common sites for cancer include the lateral borders of the tongue, the floor of the mouth, and the **oropharynx**. Rarely, cancers found in the oral region have **metastasized** from the lungs, breast, or prostate.



<http://www.1800dentist.com/adx/aspx/adxGetMedia.aspx?DocID=484,405,62,3240,1,Documents&MediaID=1805&Filename=oral-cancer.jpg>

Oral cancer can have many different appearances but typically resembles **dysplastic lesions** (eg, white, red, or mixed white-red areas that are not easily wiped away).

## **Evaluation**



**History: History of present illness** includes questions about how long the growth has been present, whether it is painful, and whether there has been any injury to the area (eg, biting a cheek, scraping by a sharp tooth edge or dental restoration). Patients are asked about symptoms of systemic illness, particularly weight loss and malaise.

**Past medical history** should seek risk factors for candidiasis, including recent antibiotic use, diabetes, and **HIV infection** (or risk factors for HIV). The amount and duration of use of alcohol and tobacco is noted.

**Physical examination:** The physical examination focuses on the mouth and neck, inspecting and palpating all areas of the mouth and throat, including under the tongue. The neck is palpated for lymphadenopathy, which suggests possible cancer or chronic infection.

**Red flags:** The following findings are of particular concern:

- Weight loss
- Neck mass

**Interpretation of findings:** The main concern is to not mistake an oral cancer or dysplastic lesion for a benign disorder. Clinicians should maintain a high degree of suspicion and refer the patient for biopsy if the lesion does not resolve in a few weeks.

**Testing:** Suspected candidiasis can be confirmed by finding yeast and **pseudohyphae** in KOH wet mounts of scrapings from a lesion. Other acute lesions, particularly those that appear related to local trauma or irritation, may be observed. However, most lesions present for more than a few weeks, and those of unknown duration, should be **biopsied** because cancer is difficult to exclude clinically.

## Treatment

Treatment depends on the cause of the growth.

## Key Points

- Most oral growths are benign.
- Warts, candidal infections, and repeated trauma are common causes of benign growths.
- Use of alcohol and tobacco is a risk factor for cancer.

- Because cancer is difficult to diagnose by inspection, biopsy is often necessary.

**Reference:** <http://www.merckmanuals.com>

eTOC在校生徒様がeTOCのレッスン  
以外の目的で使用すること及び印刷禁止。  
法律で罰せられます。  
This document is protected by copyright.  
You are breaking the law  
if you copy or distribute this file.

**eTOC**  
English Teachers On Call