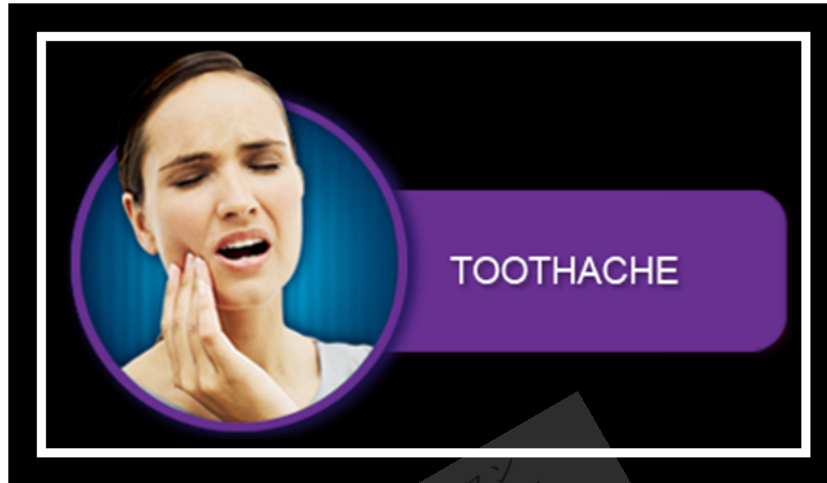

Toothache and Infection



http://www.flanaxusa.com/img/title_tooth_eng.png

Pain in and around the teeth is a common problem, particularly among patients with poor oral hygiene. Pain may be constant, felt after stimulation (eg, heat, cold, sweet food or drink, chewing, brushing), or both.

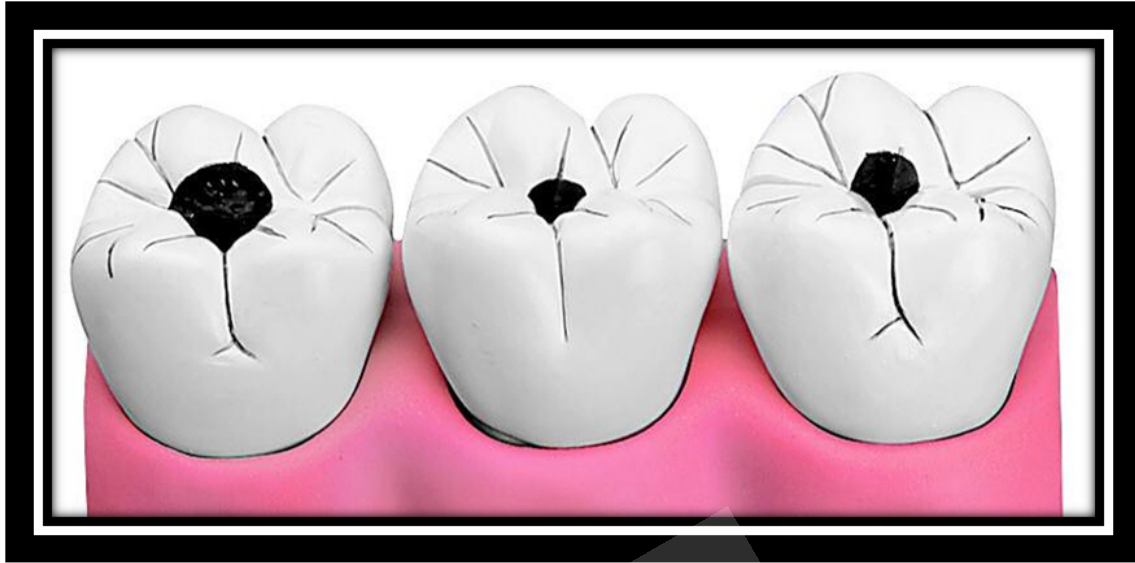Etiology

The most common causes of toothache are

- **Dental caries**
- **Pulpitis**
- **Periapical abscess**
- **Trauma**
- Erupting wisdom tooth (causing **pericoronitis**)

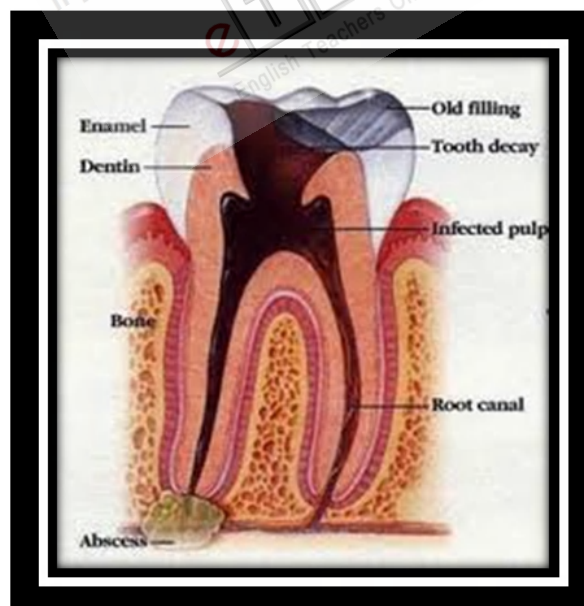
Toothache is usually caused by dental caries and its consequences.

Caries causes pain when the lesion extends through the **enamel** into **dentin**. Pain usually occurs after stimulation from cold, heat, sweet food or drink, or brushing; these stimuli cause fluid to move within **dentinal tubules** to induce a response in the pulp. As long as the discomfort does not persist after the stimulus is removed, the pulp is likely healthy enough to be maintained. This is referred to as normal dentinal sensitivity, **reversible pulpalgia**, or **reversible pulpitis**.



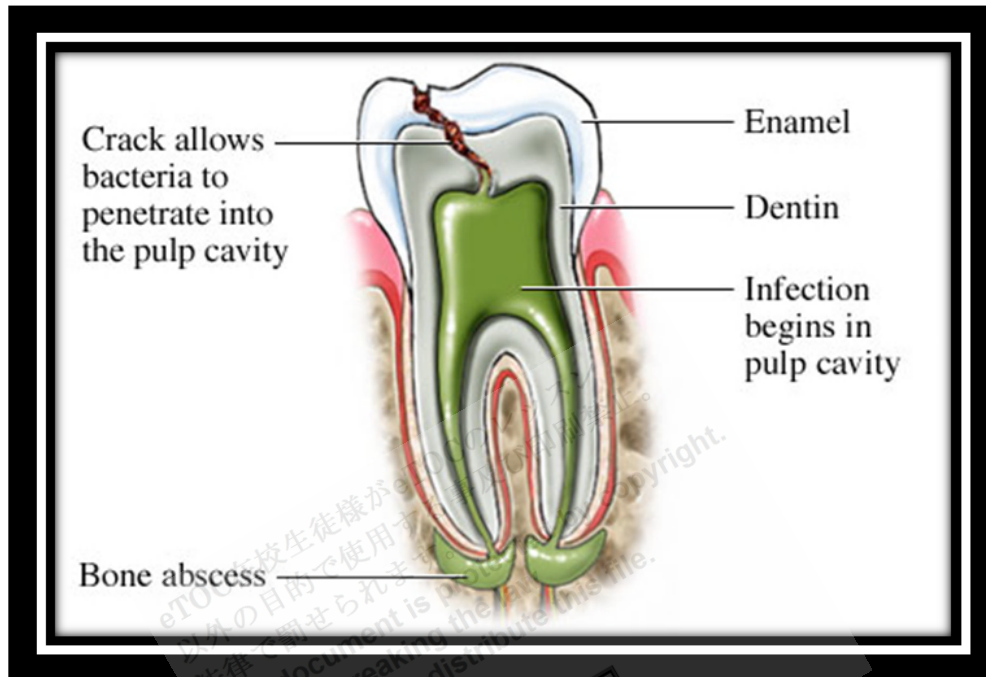
<http://www.1moreinfo.com/site/images/caries.JPG>

Pulpitis is inflammation of the pulp, typically due to advancing caries, cumulative minor pulp damage from previous large restorations, a defective restoration, or trauma. It may be reversible or irreversible. Pressure **necrosis** frequently results from pulpitis. Pain may be spontaneous or in response to stimulation, particularly heat or cold. In both cases, pain lingers for a minute or longer. Once the pulp becomes necrotic, pain ends briefly (hours to weeks). Subsequently, **periapical inflammation** (**apical periodontitis**) or an **abscess** develops.



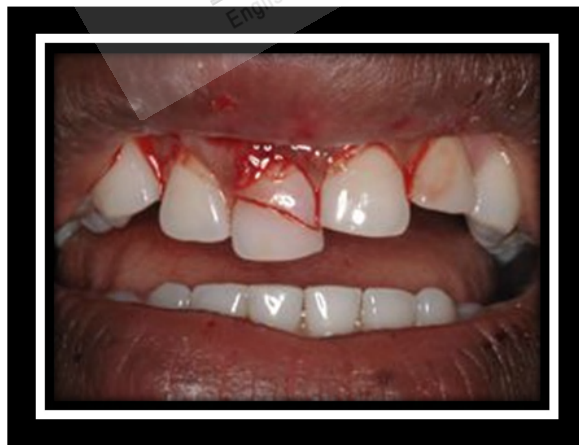http://t3.gstatic.com/images?q=tbn:ANd9GcTdMXmlyUIXmaIQ7tCiczf7XYXWk5_OFEb1d5TNUF7r-xN_5Gf

Periapical abscess may follow untreated caries or **pulpitis**. The tooth is exquisitely sensitive to percussion (tapping with a metal dental probe or tongue blade) and chewing. The abscess may point **intraorally** and eventually drain or may become a cellulitis.



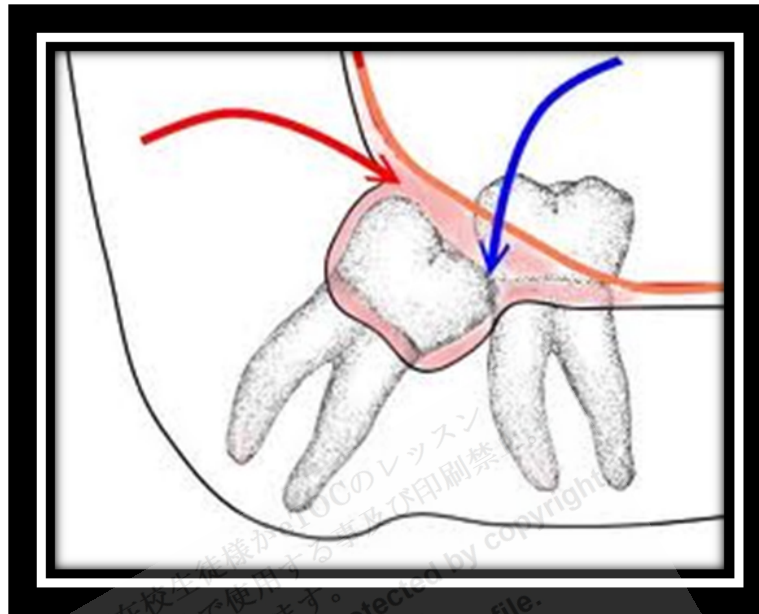
<http://toothabscess.dentalbuzz.org/wp-content/uploads/2011/06/n5551337.jpg>

Tooth trauma can damage the pulp. The damage may manifest soon after the injury or up to decades later.



http://www.dental--health.com/images/badteeth/tooth_trauma.jpg

Pericoronitis is inflammation and infection of the tissue between the tooth and its overlying flap of gingiva (**operculum**). It usually occurs in an erupting wisdom tooth (almost always a lower one).



<http://doctorspiller.com/pericoronitis.htm>

Complications: Rarely, **sinusitis** results from untreated **maxillary dental infection**. More commonly, pain from a sinus infection is perceived as originating in the (unaffected) teeth, mistakenly creating the impression of a dental origin.

Rarely, **cavernous sinus thrombosis** or **Ludwig's angina** (**submandibular space infection**) develops; these conditions are life threatening and require immediate intervention.

Table 3

Some Causes of Toothache

Cause	Suggestive Findings	Diagnostic Approach*
Apical abscess	Constant pain that worsens when chewing or biting Normally precise identification of the	Dental evaluation

	<p>involved tooth by the patient</p> <p>Tooth tender to percussion (tapping with a metal probe or tongue blade)</p> <p>Sometimes visible fluctuant swelling of mucosa over the affected root, painful swelling of the adjacent cheek and/or lip</p>	
Apical periodontitis	<p>Symptoms and findings similar to apical abscess but less severe and without swelling over the root</p>	Dental evaluation
Caries (dental sensitivity)	<p>Pain after stimulation (eg, heat, cold, sweet food or drink, brushing)</p> <p>Pain is isolated to a single tooth and usually stops when stimulus is removed</p> <p>Usually a visible carious lesion or a root surface exposed by gum recession or abrasion</p>	Dental evaluation
Incomplete fracture of the crown of a vital tooth	<p>Sharp pain on release from a chewing stroke</p> <p>Marked sensitivity to cold</p>	Dental evaluation
Irreversible pulpitis	Pain without stimulation,	Dental evaluation

	<p>lingering pain after stimulation, or both</p> <p>Usually difficulty identifying the involved tooth</p>	
<p>Pericoronitis caused by eruption or partial impaction of a 3rd molar (wisdom tooth)</p>	<p>Constant dull pain, especially with chewing</p> <p>Inflammation around the mandibular wisdom tooth, sometimes with purulent drainage</p> <p>Trismus may occur and limit opening</p>	<p>Dental evaluation</p>
<p>Pulp damage caused by trauma</p>	<p>Tooth discoloration (may be delayed up to many years after injury)</p> <p>Can result in an abscess</p>	<p>Dental evaluation</p>
<p>Reversible pulpitis</p>	<p>Similar to caries but with difficulty identifying the involved tooth</p>	<p>Dental evaluation</p>
<p>Sinusitis</p>	<p>Many maxillary posterior teeth (eg, molars, premolars) sensitive when chewing and to percussion</p> <p>Pain during posture changes, especially lowering the head (eg, tying shoe laces)</p> <p>Often nasal discharge and tenderness to percussion over the affected sinus</p>	<p>Sinus CT</p> <p>Dental evaluation if no sinusitis detected</p>

Teething

Discomfort and fussiness during tooth eruption in young children

Clinical evaluation

Drooling common, chewing on things (eg, crib rail)

Vertical root fracture

Tooth that is mobile and exquisitely sensitive to touch

Dental evaluation

Isolated deep periodontal probing depth

Characteristic "J" appearance on x-ray

*Dental evaluation entails referral to a dentist for examination and usually dental x-rays.

Evaluation

History: History of present illness should identify the location and duration of the pain and whether it is constant or present only after stimulation. Specific triggering factors to review include heat, cold, sweet food or drink, chewing, and brushing. Any preceding trauma or dental work should be noted.

Review of systems should seek symptoms of complications, including face pain, swelling, or both (**dental abscess, sinusitis**); pain below the tongue and difficulty swallowing (**submandibular space infection**); pain with bending forward (**sinusitis**); and retro-orbital headache, fever, and vision symptoms (**cavernous sinus thrombosis**).

Past medical history should note previous dental problems and treatment.

Physical examination: Vital signs are reviewed for fever.

The examination focuses on the face and mouth. The face is inspected for swelling and is palpated for induration and tenderness.

The oral examination includes inspection for gum inflammation and caries and any localized swelling at the base of a tooth that may represent a pointing **apical abscess**. If no tooth is clearly involved, teeth in the area of pain are percussed for tenderness with a tongue depressor. Also, an ice cube can be applied briefly to each tooth, removing it immediately once pain is felt. In healthy teeth, the pain stops almost immediately. Pain lingering more than a few seconds indicates pulp damage (eg, irreversible pulpitis, necrosis). The floor of the mouth is **palpated** for **induration** and **tenderness**, suggesting a deep space infection.

Neurologic examination, concentrating on the **cranial nerves**, should be done in patients with fever, headache, or facial swelling.

Red flags: Findings of particular concern are

- Headache
- Fever
- Swelling or tenderness of floor of the mouth
- Cranial nerve abnormalities

Interpretation of findings: Red flag finding of headache suggests sinusitis, particularly if multiple upper molar and **premolar** (back) teeth are painful. However, presence of vision symptoms or abnormalities of the pupils or of ocular motility suggests cavernous sinus thrombosis.

Fever is unusual with routine dental infection unless there is significant local extension. Bilateral tenderness of the floor of the mouth suggests **Ludwig's angina**.

Difficulty opening the mouth (**trismus**) can occur with any lower molar infection but is common only with **pericoronitis**.

Isolated dental condition: Patients without red flag findings or facial swelling likely have an isolated dental condition, which, although uncomfortable, is not serious. Clinical findings, particularly the nature of the pain, help suggest a cause. Because of its innervation, the pulp can perceive **stimuli** (eg, heat, cold, sweets) only as pain. An important distinction is whether there is continuous pain or pain only on stimulation and, if pain is only on stimulation, whether the pain lingers after the stimulus is removed.

Swelling at the base of a tooth, on the cheek, or both indicates infection, either **cellulitis** or **abscess**. A tender, fluctuant area at the base of a tooth suggests a pointing abscess.

Table 4

Characteristics of Pain in Toothache

Finding	Common Causes
Pain only after stimulation, no lingering pain	Reversible pulpitis (dental pain)
Pain lingers after stimulation (may have unstimulated pain)	Irreversible pulpitis
No pain with stimulation	Pulp necrosis without apical periodontitis or abscess
Continuous pain (worse when chewing or percussed; easily localized)	Apical periodontitis or abscess

Testing: Dental x-rays are the mainstay of testing but can be deferred to a dentist.

The rare cases in which cavernous sinus **thrombosis** or **Ludwig's angina** are suspected require imaging studies, typically CT or MRI.

Treatment

Analgesics are given pending dental evaluation and definitive treatment. A patient who is seen frequently for emergencies but who never receives definitive dental treatment despite availability may be seeking **opioids**.

Antibiotics directed at oral flora are given for most disorders beyond irreversible pulpitis (eg, **necrotic pulp**, **abscess**, **cellulitis**). Patients with **pericoronitis** should also receive an antibiotic. However, antibiotics can be deferred if patients can be seen the same day by a dentist, who may be able to treat the infection by removing the source (eg, by **extraction**, **pulpectomy**,

or **curettage**). When antibiotics are used, **penicillin** or **amoxicillin** is preferred, with **clindamycin** the alternative.

An **abscess** associated with well-developed (soft) **fluctuance** is typically drained through an incision with a #15 scalpel blade at the most dependent point of the swelling. A rubber drain, held by a suture, may be placed.

Pericoronitis or erupting 3rd molars are treated with **chlorhexidine** 0.12% rinses or **hypertonic saltwater** soaks (1 tbsp salt mixed in a glass of hot water—no hotter than the coffee or tea a patient normally drinks). The salt water is held in the mouth on the affected side until it cools and then is **expectorated** and immediately replaced with another mouthful. Three or 4 glasses of salt water a day may control inflammation and pain pending dental evaluation.

Teething pain in young children may be treated with weight-based doses of **acetaminophen** or **ibuprofen**. Topical treatments can include chewing hard crackers (eg, **biscotti**), applying 7.5% or 10% benzocaine gel qid (provided there is no family history of **methemoglobinemia**), and chewing on anything cold (eg, **gel-containing teething rings**).



http://1.bp.blogspot.com/-rFdZX4_Y9bs/TVRXxeV9pRI/AAAAAAAAABYg/KEwfrinXQBg/s1600/IMG_1991_small.JPG

The rare patient with **cavernous sinus thrombosis** or **Ludwig's angina** requires immediate hospitalization, removal of the infected tooth, and culture-guided parenteral antibiotics.

Geriatrics Essentials

The elderly are more prone to caries of the root surfaces, usually because of **gingival recession**. **Periodontitis** often begins in young adulthood; if untreated, tooth pain and loss are common in old age.

Key Points

- Most toothache involves dental caries or its complications (eg, **pulpitis**, **abscess**).
- Symptomatic treatment and dental referral are usually adequate.
- Antibiotics are given if signs of an abscess, necrotic pulp, or more severe conditions are present.
- Very rare but serious complications include extension of dental infection to the floor of the mouth or to the cavernous sinus.
- Dental infections rarely cause sinusitis, but sinus infection may cause pain perceived as originating in the teeth.

Reference: <http://www.merckmanuals.com>