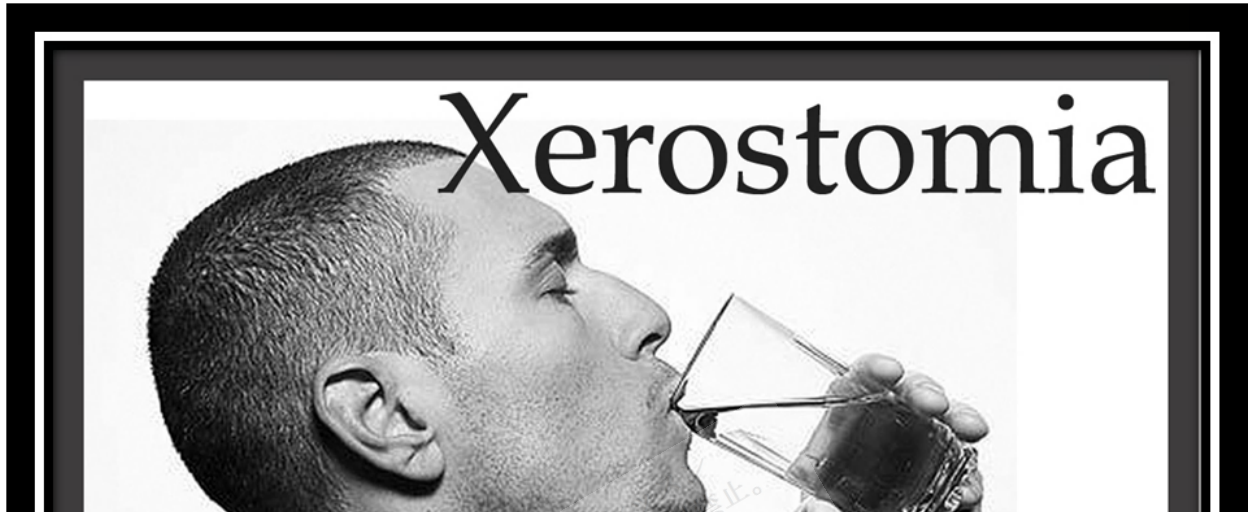


# Xerostomia



Copyright © 2018 Surely work.co

完全版テキストはレッスン前に担当講師から受け取って下さい

講師のスカイプチャットにテキスト名を送って下さい

Your teacher can send you the complete material.

Please ask them to send the complete version of this material before the lesson.

condition can result in discomfort, interfere with speech and swallowing, make wearing dentures difficult, cause **halitosis**, and impair oral hygiene by causing a decrease in oral pH and an increase in bacterial growth. Longstanding xerostomia can result in severe tooth decay and oral **candidiasis**. Xerostomia is a common complaint among older adults, affecting about 20% of the elderly.

## **Pathophysiology**

Stimulation of the oral mucosa signals the **salivatory nuclei** in the **medulla**, triggering an efferent response. The efferent nerve impulses release **acetylcholine** at salivary gland nerve terminals, activating **muscarinic receptors** (M<sub>3</sub>), which increase saliva production and flow. **Medullary signals** responsible for salivation may also be modulated by **cortical** inputs from other stimuli (eg, taste, smell, anxiety).

## Etiology

Xerostomia is usually caused by the following:

- Drugs
- Radiation to the head and neck (for cancer treatment)

Systemic disorders are less commonly the cause, but xerostomia is common in [Sjögren's syndrome](#) and may occur in HIV/AIDS, uncontrolled diabetes, and certain other disorders.

**Drugs:** Drugs are the most common cause; about 400 prescription drugs and many OTC drugs cause decreased salivation. The most common include the following:

- [Anticholinergics](#)
- [Antiparkinsonian drugs](#)
- [Antineoplastics \(chemotherapy\)](#)

Chemotherapy drugs cause severe dryness and stomatitis while they are being taken; these problems usually end after therapy is stopped.

Other common drug classes that cause xerostomia include [antihypertensives](#), [anxiolytics](#), and [antidepressants](#) (less severe with [SSRIs](#) than with [tricyclics](#)).

The rise of illicit [methamphetamine](#) use has resulted in an increasing incidence of [meth mouth](#), which is severe tooth decay caused by methamphetamine-induced xerostomia. The damage is exacerbated by the [bruxing](#) and [clenching](#) caused by the drug and by the heat of the inhaled vapor. This combination causes very rapid destruction of teeth.

Tobacco use usually causes a decrease of saliva.

**Radiation:** Incidental radiation to the salivary glands during radiation therapy for head and neck cancer often causes severe xerostomia (5200 cGy causes severe, permanent dryness, but even low doses can cause temporary drying).

**Table 5**

### Some Causes of Xerostomia

| Cause | Examples |
|-------|----------|
|-------|----------|

|              |  |
|--------------|--|
| <b>Drugs</b> |  |
|--------------|--|

|                 |                                                                                   |
|-----------------|-----------------------------------------------------------------------------------|
| Anticholinergic | Antidepressants<br>Antiemetics<br>Antihistamines<br>Antipsychotics<br>Anxiolytics |
|-----------------|-----------------------------------------------------------------------------------|

|                      |                                         |
|----------------------|-----------------------------------------|
| Recreational/illicit | Cannabis<br>Methamphetamines<br>Tobacco |
|----------------------|-----------------------------------------|

|       |                                                                                                                                                             |
|-------|-------------------------------------------------------------------------------------------------------------------------------------------------------------|
| Other | Antihypertensives<br>Antineoplastics<br>(chemotherapy<br>drugs)<br>Antiparkinsonian<br>drugs<br>Bronchodilators<br>Decongestants<br>Diuretics<br>Meperidine |
|-------|-------------------------------------------------------------------------------------------------------------------------------------------------------------|

, methadone

, and other  
opioids

|                           |  |
|---------------------------|--|
| <b>Systemic disorders</b> |  |
|---------------------------|--|

|   |                              |
|---|------------------------------|
| — | Amyloidosis<br>HIV infection |
|---|------------------------------|

Leprosy  
Sarcoidosis  
Sjögren's  
syndrome  
TB

#### Other

— Excessive mouth  
breathing  
Head and neck  
trauma  
Radiation  
treatment  
Viral infections

### Evaluation

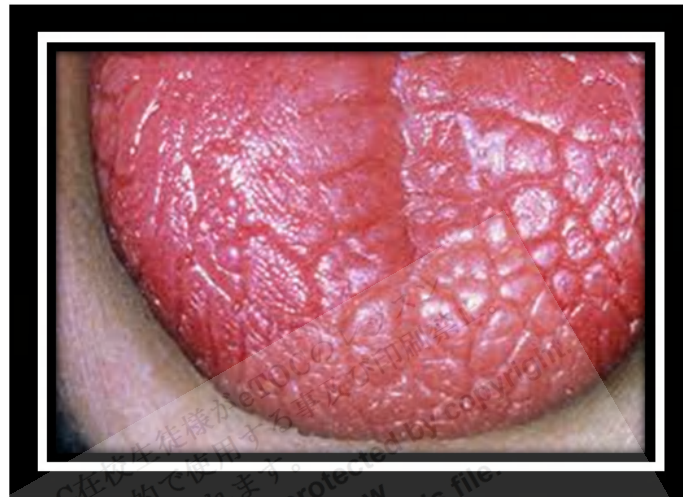**History: History of present illness** should include acuity of onset, temporal patterns (eg, constant vs intermittent, presence only on awakening), provoking factors, including situational or psychogenic factors (eg, whether xerostomia occurs only during periods of psychologic stress or certain activities), assessment of fluid status (eg, fluid intake habits, recurrent vomiting or diarrhea), and sleeping habits. Use of recreational drugs should be specifically elicited.

**Review of systems** should seek symptoms of causative disorders, including dry eyes, dry skin, rashes, and joint pain ([Sjögren's syndrome](#)).

**Past medical history** should inquire about conditions associated with xerostomia, including [Sjögren's syndrome](#), history of radiation treatment, head and neck trauma, and a diagnosis of or risk factors for HIV infection. Drug profiles should be reviewed for potential offending drugs.

**Physical examination:** Physical examination is focused on the oral cavity, specifically any apparent dryness (eg, whether the [mucosa](#) is dry, sticky, or moist; whether saliva is foamy, thick, stringy, or normal in appearance), the presence of any lesions caused by [Candida albicans](#), and the condition of the teeth.

The presence and severity of xerostomia can be assessed in several ways. For example, a tongue blade can be held against the **buccal mucosa** for 10 sec. If the tongue blade falls off immediately when released, salivary flow is considered normal. The more difficulty encountered removing the tongue blade, the more severe the xerostomia. In women, the lipstick sign, where lipstick adheres to the front teeth, may be a useful indicator of xerostomia.



[http://t1.gstatic.com/images?q=tbn:ANd9GcQZ\\_1K6wD5ghdt381j-WrbMeoISBbNnIcWdmZxiehjEkDRiihyQ](http://t1.gstatic.com/images?q=tbn:ANd9GcQZ_1K6wD5ghdt381j-WrbMeoISBbNnIcWdmZxiehjEkDRiihyQ)

If there appears to be dryness, the **submandibular, sublingual, and parotid glands** should be **palpated** while observing the ductal openings for saliva flow. The openings are at the base of the tongue anteriorly for the submandibular and sublingual glands and on the middle of the inside of the cheek for the parotid glands. Drying the duct openings with a gauze square before palpation aids observation. If a graduated container is available, the patient can expectorate once to empty the mouth and then expectorate all saliva into the container. Normal production is 0.3 to 0.4 mL/min. Significant xerostomia is 0.1 mL/min.

Dental caries may be sought at the margins of restorations or in unusual places (eg, at the **gum line, incisal edges, or cusp tips of the teeth**).

A common manifestation of *C. albicans* infection is areas of erythema and atrophy (eg, loss of papillae on the dorsum of the tongue). Less common is the better-known white, cheesy curd that bleeds when wiped off.

**Red flags:** The following findings are of particular concern:

- Extensive tooth decay
- Concomitant dry eyes, dry skin, rash, or joint pain
- Risk factors for HIV

**Interpretation of findings:** Xerostomia is diagnosed by symptoms, appearance, and absence of salivary flow when massaging the salivary glands.

No further assessment is required when xerostomia occurs after initiation of a new drug and stops after cessation of that drug or when symptoms appear within several weeks of irradiation of the head and neck. Xerostomia that occurs with abrupt onset after head and neck trauma may be caused by nerve damage.

**Concomitant** presence of dry eyes, dry skin, rash, or joint pain, particularly in a female patient, suggests a diagnosis of **Sjögren's syndrome**. Severe tooth discoloration and decay, out of proportion to expected findings, may be indicative of illicit drug use, particularly **methamphetamines**. Xerostomia that occurs only during nighttime or that is noted only on awakening may be indicative of excessive mouth breathing in a dry environment.

**Testing:** For patients in whom the presence of xerostomia is unclear, **sialometry** can be conducted by placing collection devices over the major duct orifices and then stimulating salivary production with citric acid or by chewing **paraffin**. Normal parotid flow is 0.4 to 1.5 mL/min/gland. Flow monitoring can also help determine response to therapy.

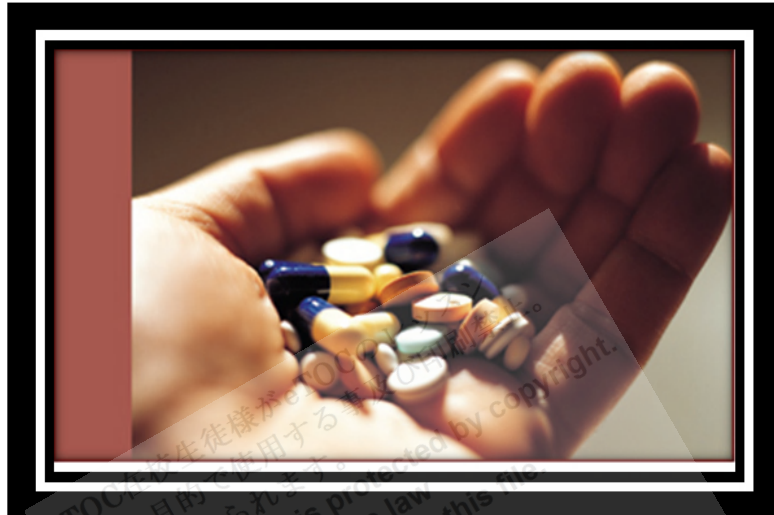The cause of xerostomia is often apparent, but if the etiology is unclear and systemic disease is considered possible, further assessment should be pursued with biopsy of a minor salivary gland (for detection of Sjögren's syndrome, **sarcoidosis**, **amyloidosis**, TB, or cancer) and HIV testing. The lower lip is a convenient site for biopsy.

## Treatment

When possible, the cause of xerostomia should be addressed and treated.

For patients with drug-related xerostomia whose therapy cannot be changed to another drug, drug schedules should be modified to achieve maximum drug effect during the day, because nighttime xerostomia is more likely to cause caries. Custom-fitted acrylic night guards carrying fluoride gel may

also help limit caries in these patients. For all drugs, easy-to-take formulations, such as liquids, should be considered, and sublingual dosage forms should be avoided. The mouth and throat should be lubricated with water before swallowing capsules and tablets or before using [sublingual nitroglycerin](#). Patients should avoid [decongestants](#) and [antihistamines](#).



[http://www.dimensionsofdentalhygiene.com/uploadedimages/DDH/Magazine/2005/07\\_July/med\\_head.jpg](http://www.dimensionsofdentalhygiene.com/uploadedimages/DDH/Magazine/2005/07_July/med_head.jpg)

Patients using continuous positive airway pressure for obstructive sleep apnea may benefit from using the humidifier function of the device. Patients using oral appliance therapy may benefit from a room humidifier.

**Symptom control:** Symptomatic treatment consists of measures that do the following:

- Increase existing saliva
- Replace lost secretions
- Control caries

Drugs that augment saliva production include [cevimeline](#) and [pilocarpine](#), both cholinergic agonists. Cevimeline (30 mg po tid) has less M<sub>2</sub> (cardiac) receptor activity [thanpilocarpine](#) and a longer half-life. The main adverse effect is nausea. [Pilocarpine](#) (5 mg po tid) may be given after ophthalmologic and cardiorespiratory contraindications are excluded; adverse effects include [sweating](#), [flushing](#), and [polyuria](#).

Sipping sugarless fluids frequently, chewing **xylitol-containing gum**, and using an OTC saliva substitute containing **carboxymethylcellulose**, **hydroxyethylcellulose**, or **glycerin** may help. Petroleum jelly can be applied to the lips and under dentures to relieve drying, cracking, soreness, and mucosal trauma. A cold-air humidifier may aid mouth breathers who typically have their worst symptoms at night.

Meticulous oral hygiene is essential. Patients should brush and floss regularly (including just before bedtime) and use **fluoride rinses** or gels daily; using newer toothpastes with added Ca and phosphorous also may help avoid rampant caries. An increased frequency of preventive dental visits with plaque removal is advised. The most effective way to prevent caries is to sleep with individually fitted carriers containing 1.1% **Na fluoride** or 0.4% stannous fluoride. In addition, a dentist can apply a 5% Na fluoride varnish 2 to 4 times/yr.

Patients should avoid sugary or acidic foods and beverages and any irritating foods that are dry, spicy, astringent, or excessively hot or cold. It is particularly important to avoid ingesting sugar near bedtime.

### **Geriatrics Essentials**

Although xerostomia becomes more common among the elderly, this is probably due to the many drugs typically used by the elderly rather than aging itself.

### **Key Points**

- Drugs are the most common cause, but systemic diseases (most commonly Sjögren's syndrome or HIV) and radiation therapy also can cause xerostomia.
- Symptomatic treatment includes increasing existing saliva flow with stimulants or drugs, and artificial saliva replacement; xylitol-containing gum and sugarless candy may be useful.
- Patients with xerostomia are at high risk of tooth decay; meticulous oral hygiene, additional preventive measures in home care, and professionally applied fluorides are essential.

**Reference:** <http://www.merckmanuals.com>