

Mandibular Dislocation

Spontaneous mandibular dislocation usually occurs in people with a history of such dislocations. Although a dislocated mandible is occasionally caused by trauma, the initiating episode is typically a wide opening followed by biting pressure (eg, biting into a large sandwich with hard bread), a wide yawn, or a dental procedure. People prone to dislocation may have naturally loose **temporomandibular joint (TMJ) ligaments**.

Patients present with a wide-open mouth that they are unable to close. Pain is secondary to patients' attempts to close the mouth. If the mandibular midline deviates to one side, the dislocation is unilateral. Although rarely used, a local anesthetic (eg, 2% **lidocaine** 2 to 5 mL) injected into the **ipsilateral** joint and into the adjacent area of insertion of the lateral

Copyright © 2018 Surely work.co

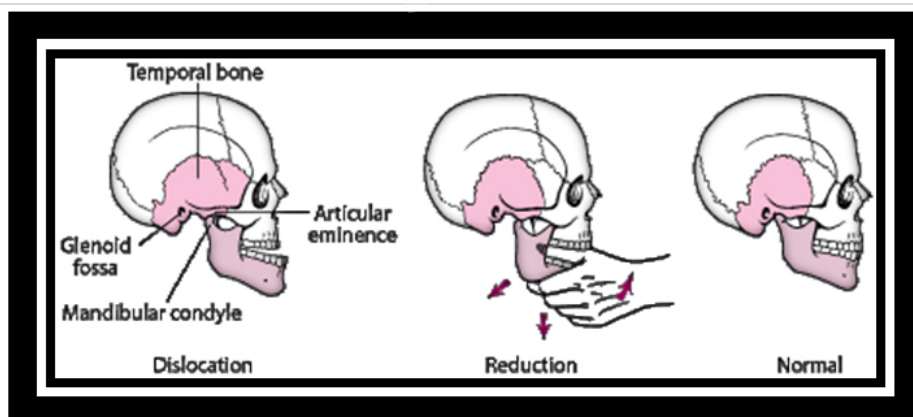
完全版テキストはレッスン前に担当講師から受け取って下さい

講師のスカイプチャットにテキスト名を送って下さい

Your teacher can send you the complete material.

Please ask them to send the complete version of this material before the lesson.

Mandibular reduction.



The patient's head is stabilized. The operator's thumbs are

placed on the **external oblique** line of the mandible (lateral to the 3rd molar area) or, after wrapping the thumbs in gauze, on the **occlusal surface** of the lower molars. The other fingers are curled under the mandible. The patient is asked to open wide, as if yawning, and the operator then applies downward force on the molars while applying upward force over the chin until the mandible reduces.

Barton bandage may be needed for 2 or 3 days. Most importantly, the patient must avoid opening the mouth wide for at least 6 wk. When anticipating a yawn, the patient should place a fist under the chin to prevent wide opening. Food must be cut into small pieces. If the patient suffers from chronic dislocations and more conservative treatment modalities have been exhausted, an oral and **maxillofacial surgeon** may be consulted. As last-resort treatments, the ligaments around the TMJ can be surgically tightened (shortened) in an attempt to stabilize the joint or the **articular eminence** can

Copyright © 2018 Surely work.co

完全版テキストはレッスン前に担当講師から受け取って下さい

講師のスカイプチャットにテキスト名を送って下さい

Your teacher can send you the complete material.

Please ask them to send the complete version of this material before the lesson.