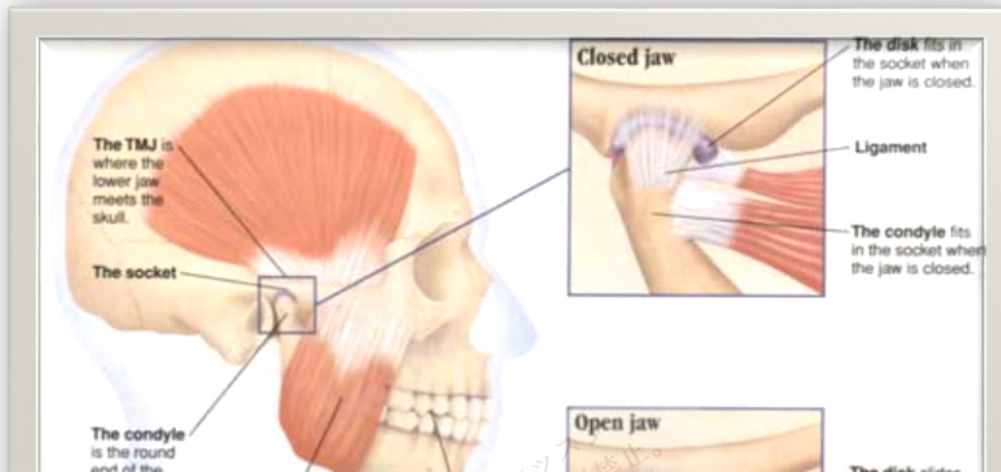


# Internal Joint Derangement



Copyright © 2018 Surely work.co

完全版テキストはレッスン前に担当講師から受け取って下さい

講師のスカイプチャットにテキスト名を送って下さい

Your teacher can send you the complete material.

Please ask them to send the complete version of this material before the lesson.

*Symptoms are localized joint pain and popping on jaw movement. Diagnosis is based on history and physical examination. Treatment is with **analgesics**, jaw rest, muscle relaxation, physical therapy, and **bite splinting**. If these methods fail, surgery may be necessary. Early treatment greatly improves results.*

The superior head of the **lateral pterygoid** muscle may pull the articular disk out of place when abnormal jaw mechanics place unusual stress on the joint. Abnormal jaw mechanics can be due to congenital or acquired asymmetries or to the **sequelae** of trauma or arthritis. If the disk remains anterior, the derangement is said to be without reduction. Restricted jaw opening (locked jaw) and pain in the ear and around the **temporomandibular joint** result. If at some point in the joint's excursion the disk returns to the head of the **condyle**, it is said to be with reduction. Derangement with reduction occurs in about one third of the population at some point. All types of derangement

can cause capsulitis (or **synovitis**), which is inflammation of the tissues surrounding the joint (eg, tendons, ligaments, connective tissue, **synovium**). Capsulitis can also occur spontaneously or result from arthritis, trauma, or infection.

### **Symptoms and Signs**

Derangement with reduction often causes a clicking or popping sound when the mouth is opened. Pain may be present, particularly when chewing hard foods. Patients are often embarrassed because they think others can hear noise when they chew. Indeed, although the sound seems louder to the patient, others can sometimes hear it.

Derangement without reduction usually causes no sound, but maximum opening between the tips of the upper and lower incisors is reduced from the normal 40 to 45 mm to  $\leq 30$  mm. Pain and a change in the patients' perception of their bite generally result.

Capsulitis results in localized joint pain, tenderness, and, sometimes, restricted opening.

### **Diagnosis**

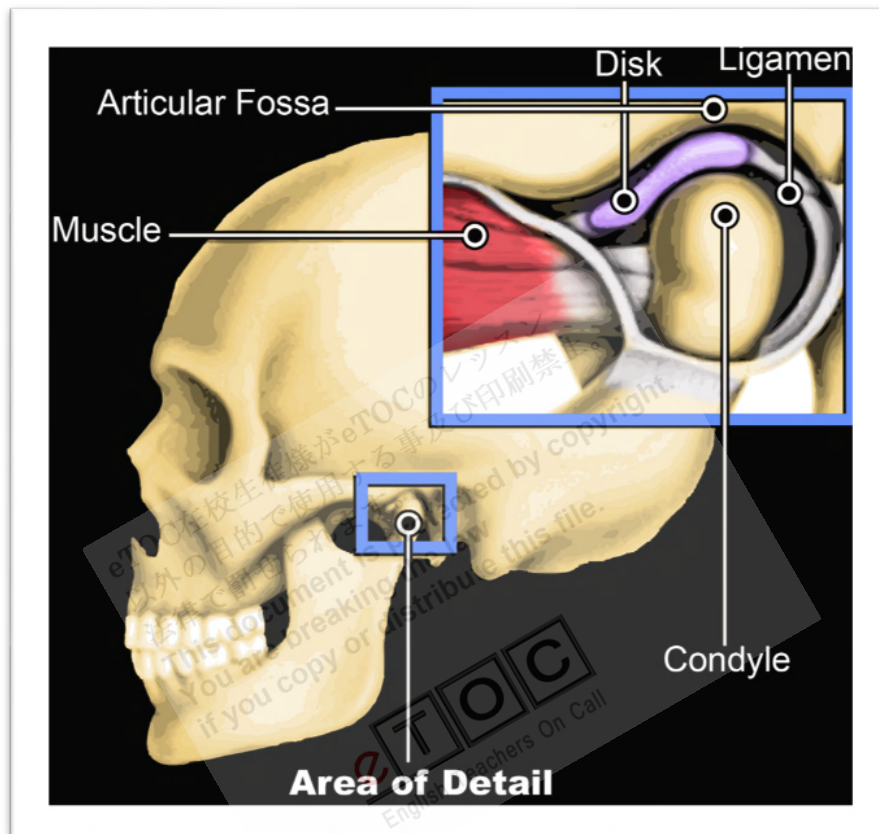
- Clinical evaluation

Diagnosis of derangement with reduction requires observation of the jaw when the mouth is opened. When the jaw is opened  $> 10$  mm (measured between upper and lower incisors), a click or pop is heard or a catch is felt as the disk pops back over the head of the condyle. The condyle remains on the disk during further opening. Usually, another click is heard during closing when the condyle slips over the posterior rim of the disk and the disk slips forward (reciprocal clicking).

Diagnosis of derangement without reduction requires that the patient open as wide as possible. The opening is measured, and gentle pressure is then exerted to open the mouth a little wider. Normally, the jaw opens about 45 to 50 mm; if the disk is deranged, it will open about 20 mm. Closing or protruding the jaw against resistance worsens the pain.

MRI is usually done to confirm presence of derangement or to determine why a patient is not responding to treatment.

**Capsulitis** is often diagnosed based on a history of injury or infection along with exquisite tenderness over the joint and by exclusion when pain remains after treatment for **myofascial pain syndrome**, disk derangement, arthritis, and **structural asymmetries**. However, capsulitis may be present with any of these conditions.



[http://activereliefla.com/wp-content/uploads/2010/03/TMJ\\_pic\\_copy\\_2.jpg](http://activereliefla.com/wp-content/uploads/2010/03/TMJ_pic_copy_2.jpg)

[http://activereliefla.com/wp-content/uploads/2010/03/TMJ\\_pic\\_copy\\_2.jpg](http://activereliefla.com/wp-content/uploads/2010/03/TMJ_pic_copy_2.jpg)

### **Treatment**

- **Analgesics** as needed
- Sometimes repositioning splint or surgery
- Sometimes **corticosteroid injection** for capsulitis

Derangement with reduction does not require treatment if the patient can open reasonably wide (about 40 mm or the width of the index, middle, and ring fingers) without discomfort. If pain occurs, mild analgesics, such as NSAIDs (ibuprofen 400 mg po q 6 h), can be used. If onset is < 6 mo, an anterior repositioning splint may be used to position the mandible forward and on the disk. The splint is a horseshoe-shaped appliance of hard,

**transparent acrylic** (plastic) made to fit snugly over the teeth of one arch. Its chewing surface is designed to hold the mandible forward when the patient closes on the splint. In this position, the disk is always on the head of the condyle. The splint is gradually adjusted to allow the mandible to move posteriorly. If the disk stays with the condyle as the superior head of the **external pterygoid** stretches, the disk is said to be captured. The longer the disk is displaced, the more deformed it becomes and the less likely repositioning will succeed. Surgical plication of the disk may be done, with variable success.

Derangement without reduction may not require treatment other than analgesics. Splints may help if the articular disk has not been significantly deformed, but long-term use may result in irreversible changes in oral architecture. In some cases, the patient is instructed to slowly stretch the disk out of position, which allows the jaw to open normally. Various arthroscopic and open surgical procedures are available when conservative treatment fails.

**Capsulitis** is initially treated with NSAIDs, jaw rest, and muscle relaxation. If these treatments are unsuccessful, corticosteroids may be injected into the joint, or **arthroscopic joint lavage** and **debridement** are used.