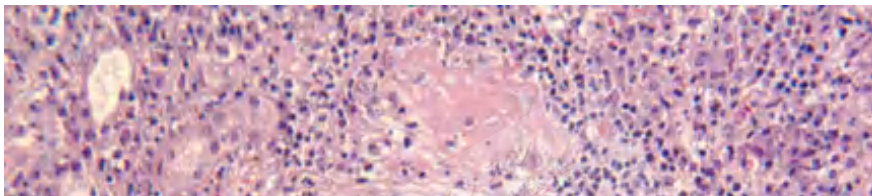


Crescentic Glomerulonephritis (RPGN)

Background

Rapidly progressive glomerulonephritis (RPGN) is defined as any glomerular disease characterized by extensive crescents (usually >50%) as the principal histologic finding and by a rapid loss of renal function (usually a 50% decline in the glomerular filtration rate [GFR] within 3 mo) as the clinical correlate.

The image shown below depicts the histologic findings observed in patients with severe types of RPGN.



Copyright © 2018 Surely work.co

完全版テキストはレッスン前に担当講師から受け取って下さい

講師のスカイプチャットにテキスト名を送って下さい

Your teacher can send you the complete material.

Please ask them to send the complete version of this material before the lesson.

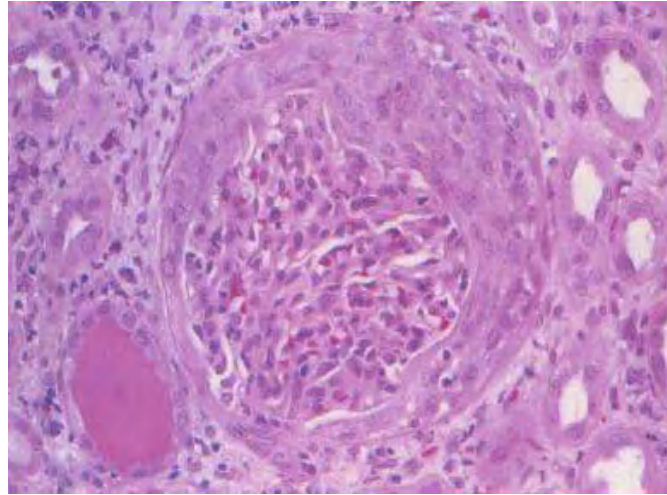


S. Meleg-Smith, Pathology, Tulane U.

Glomerulonephritis, crescentic. Light microscopy (200x hematoxylin and eosin stain): The normal renal architecture is lost. The glomerulus (*) is solid and hypercellular and surrounded by severe interstitial inflammatory infiltrate. Image courtesy of Suzanne Meleg-Smith, MD, Department of Pathology, Tulane University School of Medicine, New Orleans.

Transient [azotemia](#) with oliguria is common in patients with [acute glomerulonephritis](#).

Some patients have acute glomerulonephritis and present with rapidly progressive renal failure that develops within weeks to months and displays little tendency for spontaneous or complete recovery. Glomerular crescents can complicate any glomerulopathy, even noninflammatory glomerulopathy. In patients with noninflammatory glomerulopathies, the crescents tend to be fibrotic rather than cellular. Cellular crescents are a manifestation of a severe inflammatory process.

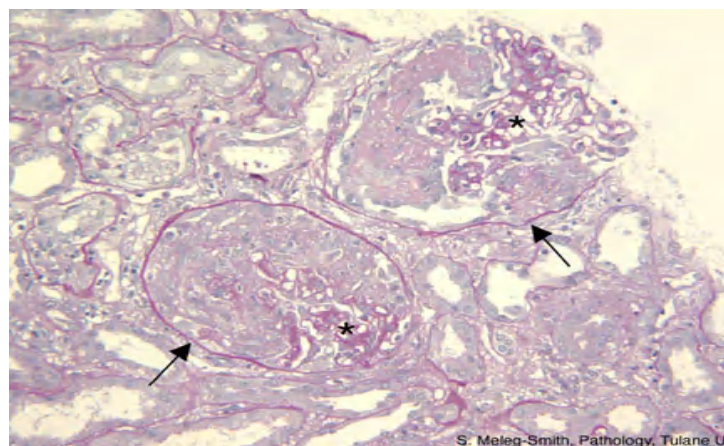


Glomerulonephritis, crescentic. Light microscopy (25x hematoxylin and eosin stain): Compression of the glomerular tuft with a circumferential cellular crescent that occupies most of the Bowman space. Image courtesy of Madeleine Moussa, MD, FRCPC, Department of Pathology, London Health Sciences Centre, London, Ontario, Canada.

Classification

Idiopathic or primary crescentic glomerulonephritis is classified into the following types:

- Type I with linear deposits of immunoglobulin G (IgG) (anti-glomerular basement membrane [GBM] disease)
- Type II with granular deposits of immunoglobulin (immune-complex mediated)
- Type III with few or no immune deposits (pauci-immune) - Antineutrophil cytoplasmic antibody (ANCA)-associated (Renal-limited forms of ANCA-associated crescentic glomerulonephritis are thought to be related to small vessel vasculitis [SVV] with exclusive involvement of the glomerular capillaries.)
- Type IV combinations of types I and III
- Type V ANCA-negative renal vasculitis (5-10%)



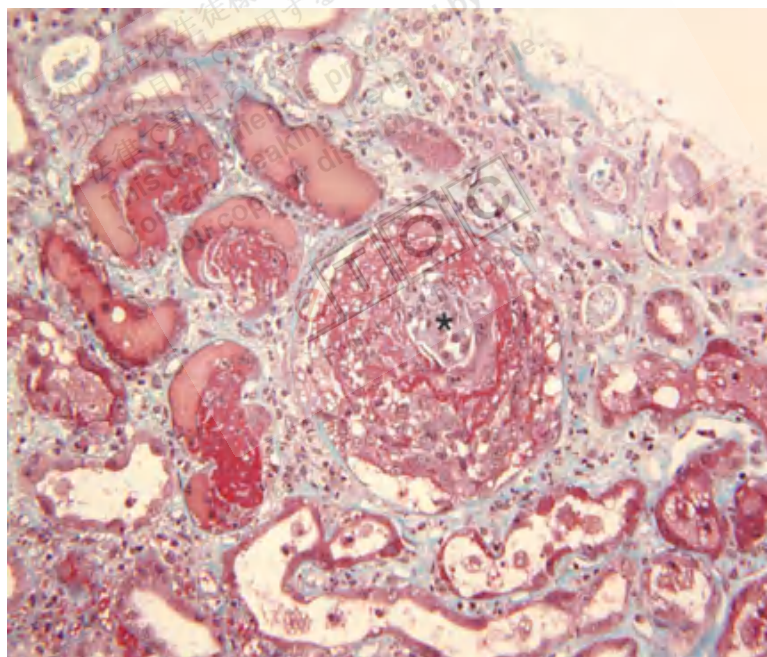
S. Meleg-Smith, Pathology, Tulane U.

Glomerulonephritis, crescentic. Light microscopy (200x periodic acid-Schiff stain): Bowman capsule (arrow) surrounds each glomerulus. The glomerular tuft (*) is distorted by a proliferation of epithelial cells (crescent), which replaces the urinary space. Image courtesy of Suzanne Meleg-Smith, MD, Department of Pathology, Tulane University School of Medicine, New Orleans.

Pathophysiology

RPGN can develop in any of the following clinical settings:

- Complication of acute or subacute infectious process
- Renal complication of multisystem disease: Secondary forms comprise more than 40% of cases.
- In association with use of certain drugs: A review of published data on an association between hydrocarbon exposure and anti-GBM antibody-mediated disease suggests the possibility of a casual relationship.
- Primary glomerular disease in which the kidney is the sole organ involved and in which extrarenal manifestations are caused by renal function disturbances



Glomerulonephritis, crescentic. Light microscopy (400x trichrome stain): The remnant of the glomerular tuft (*) is surrounded by the cellular crescent with abundant fibrin—red on trichrome stain. Interstitial edema separates the tubules, and scarce inflammatory cells are present. Image courtesy of Suzanne Meleg-Smith, MD, Department of Pathology, Tulane University School of Medicine, New Orleans.

Acute RPGN is mediated by antibody or cellular immunity or by interaction of the two arms of the immune system. Deposition of antibody along the basement membrane and/or glomerular deposition of preformed soluble immune complexes can result in glomerulonephritis.

Lymphocytes and macrophages, along with deposited antibody, are important in the production of proliferation and proteinuria. The involved lymphocytes are identified as T cells; most are helper T cells with some suppressor T cells. Antibody- and cell-mediated immunity are together responsible for many lesions observed in patients with acute RPGN, and cell-mediated immunity without antibody may produce crescentic glomerulonephritis.

Crescents are defined as the presence of 2 or more layers of cells in the Bowman space. The presence of crescents in glomeruli is a marker of severe injury.

The initiating event is the development of a physical disruption in the GBM. The lesions are mediated by processes involving macrophages and cell-mediated immunity. Following disruption of the glomerular capillary, circulating cells, inflammatory mediators, and plasma proteins pass through the capillary wall into the Bowman space. Cells and mediators from the interstitium enter the Bowman space with disruption of the Bowman capsule, which leads to development of crescents.

The major participants in crescent formation are coagulation proteins, macrophages, T cells, fibroblasts, and parietal epithelial cells. Activated macrophages contribute to the crescents by proliferating and releasing procoagulant tissue factor, interleukin-1 (IL-1) and tumor necrosis factor (TNF). T cells are not prominent components, but they play an important role in glomerular injury by antigen recognition and macrophage recruitment.

The reversibility of crescents correlates with relative predominance of cellular components. Whether crescents progress or resolve may depend upon the integrity of the Bowman capsule and resulting cellular composition of the crescent. Progression to fibrous crescents is more common when capsular rupture occurs and fibroblasts along with macrophages are prominent in the Bowman space. The presence of fibrous crescents usually correlates with glomerular sclerosis or irreversibility.

Epidemiology

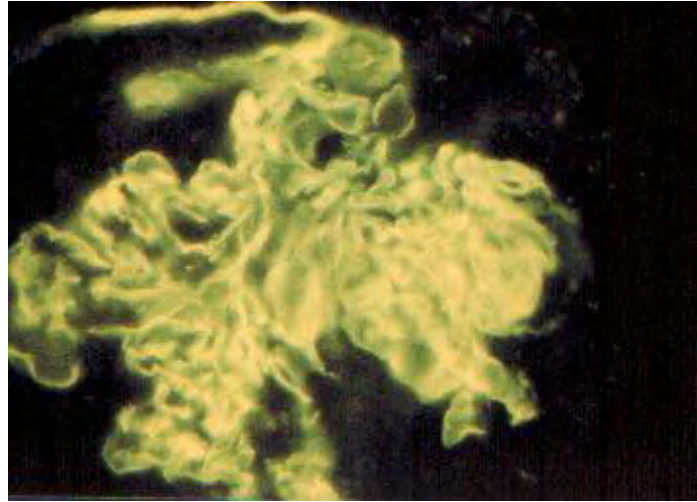
Frequency

United States

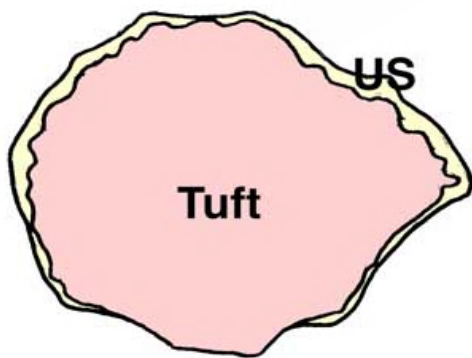
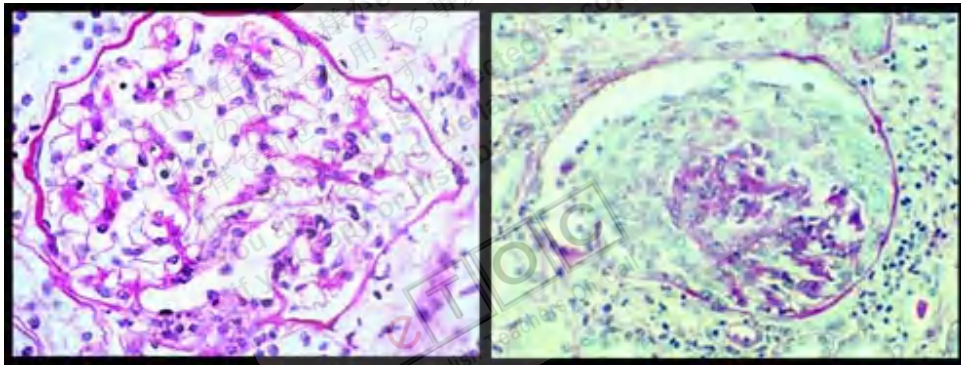
Idiopathic crescentic glomerulonephritis accounts for fewer than 10% of all patients presenting with primary glomerulopathy. RPGN type III is more common than RPGN types I or II. More than 50% of patients with crescentic glomerulonephritis present with acute nephritic syndrome and rapidly deteriorating renal function; however, other modes do occur (eg, asymptomatic, 15%; nephrotic, 10%; chronic renal failure, 15%).

International

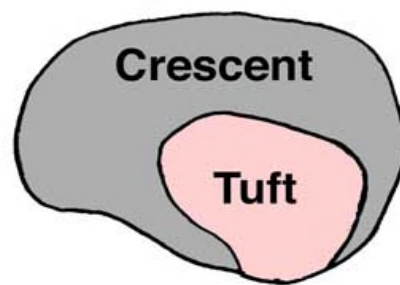
Peak incidence of anti-GBM disease occurs in spring and early summer. No seasonal predilection is observed in patients with non-anti-GBM disease.



Glomerulonephritis, crescentic. Immunofluorescence (25x): Anti-glomerular basement membrane characterized by the presence of linear immunoglobulin G deposit along the glomerular basement membrane. Image courtesy of Madeleine Moussa, MD, FRCPC, Department of Pathology, London Health Sciences Centre, London, Ontario, Canada.



Normal



Crescent

Mortality/Morbidity

Renal failure at presentation carries an increased risk for [end-stage renal disease](#) and death despite immunosuppressive therapy.^[1] Death or dialysis occurs in 73% of patients who are treated with conventional therapy and in 88% of patients if they are oligoanuric at time of presentation.

Race

No racial predilection exists.

Sex

For RPGN types I and III, a predilection for males exists.

Age

RPGN has a broad age distribution, as follows:

- RPGN type I generally occurs in young adults.
- RPGN types II and III generally occur in older adults; the peak incidence occurs in the fourth to sixth decades of life.

History

Clinical and laboratory presentations of all types of acute RPGN are quite similar.^[2]

- Some patients present with signs and symptoms of renal disease, for example, anemia, hematuria, fluid retention, oliguria, or even uremia.
- Symptoms of weakness, nausea, and vomiting (indicative of azotemia) usually dominate the clinical picture.
- Other patients present with signs and symptoms of their primary etiology (eg, Goodpasture syndrome, Wegener granulomatosis, systemic lupus erythematosus [SLE]).
- Still others give a history of a flulike or viral prodrome. Vague aches and pains or frank arthritis, sinusitis, otitis, episcleritis, skin rash, neuritis, or encephalopathy are uncommon and are more common with a multisystem disease (suggesting secondary form).
- Oliguria, abdominal or flank pain, and hemoptysis may occur (eg, Goodpasture syndrome).
- Peripheral swelling may be present.
- Fifteen percent of patients may be asymptomatic.

Physical

- Blood pressure may be normal or slightly elevated.
- Peripheral edema may be present in 10% of patients.
- Pallor is common.
- Skin rash: A lesion suggesting leukocytoclastic vasculitis may be present.

Causes

- Infectious diseases
 - Poststreptococcal glomerulonephritis (PSGN)
 - Infective endocarditis
 - Occult visceral sepsis
 - Hepatitis B infection (with vasculitis and/or cryoglobulinemia)
- Multisystem diseases
 - SLE
 - Henoch-Schönlein purpura
 - Systemic necrotizing vasculitis (including Wegener granulomatosis)
 - Microscopic polyarteritis
 - Goodpasture syndrome
 - Essential mixed (IgG and immunoglobulin M [IgM]) cryoglobulinemia
 - Malignancy
 - Relapsing polychondritis
 - Rheumatoid vasculitis
- Drugs
 - Penicillamine
 - Hydralazine (rare case reports)
 - Allopurinol (with vasculitis)
 - Rifampin (rare case reports)
 - Propylthiouracil, thiamazole, carbimazole, benzylthiouracil
 - Aminoguanidine
- Primary glomerular disease
 - Idiopathic or primary crescentic glomerulonephritis
 - Type I with linear deposits of IgG (anti-GBM disease)
 - Type II with granular deposits of immunoglobulin (immune-complex mediated)
 - Type III with few or no immune deposits (pauci-immune) - ANCA-associated (renal-limited microscopic polyarteritis)
 - Type IV combinations of types I and IIIa
 - Type V ANCA-negative renal vasculitis (5-10%)
- Superimposed on another primary glomerular disease
 - Membranoproliferative glomerulonephritis (MPGN) type II
 - Membranous glomerulonephritis
 - Immunoglobulin A (IgA) nephropathy

Reference:

<http://emedicine.medscape.com>

<http://renux.dmed.ed.ac.uk>